



PATIENT

Penelope Spirto

SPECIES

Canine

BREED

Pit Bull Mix

SEX

Spayed Female

AGE

8 Months

INTERPRETED BY

Nele Eley, DVM
Dr. med. Vet. DipECVDI

HOSPITAL NAME

Blandford Animal
Hospital

REFERRING VET

Lapierre

INVOICE

53637

DATE

8-22-22

PRESENTING CLINICAL SIGNS

Came as rescue from Texas and no confirmed history. Seen on 8/17/22 for suspect kennel cough, put on diphenoxylate and doxycycline without positive response. Coughing frequently through the day sometimes producing bile or foamy mucous. Huffing coughs during PE. Activity level is beginning to decline.

Abnormal PE/Chem/CBC/UA Results: Moderately raspy sounds ausculted all lung fields. Huffing cough several times during physical exams; esp if owner holds Penelope in gentle bear hug for exam.

RADIOGRAPHIC STUDY OF THE THORAX

Right and left lateral views of the thorax totaling 2 images available for review.

RADIOGRAPHIC FINDINGS

The cardiac silhouette and trachea present within normal limits.

The lungs are deeply inflated. A moderate to severe generalized bronchial lung pattern with marked peribronchial cuffing is seen throughout the lung with even distribution throughout the entire lung field.

The thoracic boundaries present within normal limits.

Mild gastric aerophagia is noted.

RADIOGRAPHIC DIAGNOSIS

- Moderate to severe generalized active bronchial lung pattern.

INTERPRETATION OF THE FINDINGS & FURTHER RECOMMENDATIONS

The radiographic findings are suggestive for severe active lower airway disease. Infectious bronchitis including tracheobronchitis such as viral, bacterial, mixed, or parasitic is a potential as well as eosinophilic / allergic bronchopneumopathy. Further definition by means of lungworm testing and airway endoscopy with airway sampling could be considered.



PATIENT

Penelope Spirto

SPECIES

Canine

BREED

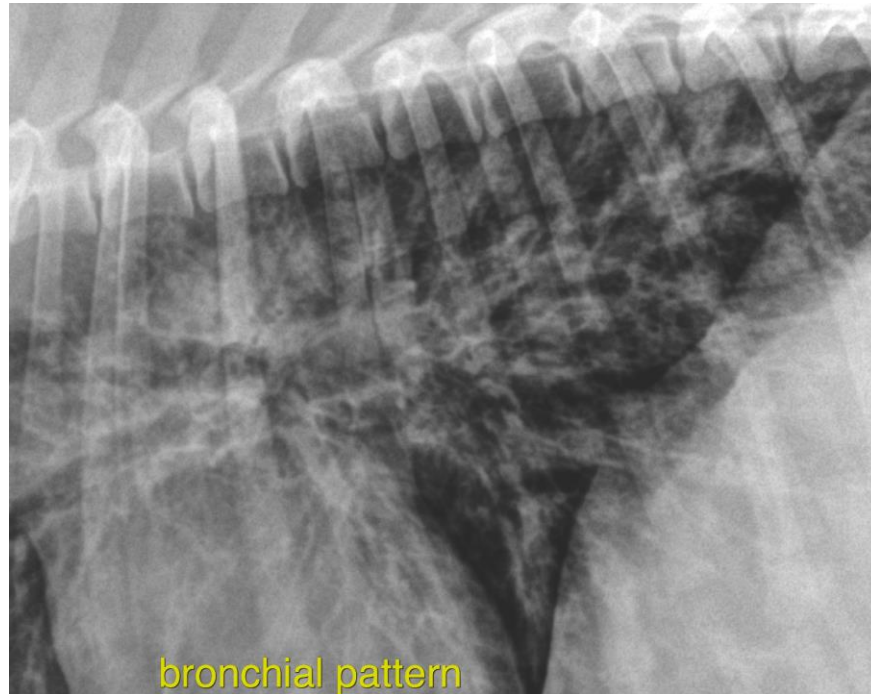
Pit Bull Mix

SEX

Spayed Female

AGE

8 Months



INTERPRETED BY

Nele Eley, DVM
Dr. med. Vet. DipECVDI

The information and recommendations provided are based on the images presented by the referring veterinarian/sonographer. No evaluation can be communicated regarding pathology that was not visible in the image/video clips provided.

Thank you for this referral. If the clinical or image interpretation does not parallel your findings or if I can be of any further assistance please contact me.

HOSPITAL NAME

Blandford Animal
Hospital

Nele Eley, DVM, Dr. med. vet., DipECVDI
European Specialist in Veterinary Diagnostic Imaging, Cert. Radiology,
Senior lecturer University of Giessen, Germany, Veterinary Faculty, Department of Radiology
Nele.Eley@sonopath.com

REFERRING VET

Lapierre

INVOICE

53637

DATE

8-22-22