

**PATIENT**

Bennett Millaud

PRESENTING CLINICAL SIGNS

History of seizures, ruling out brain VF vs. other

SPECIES

Canine

COMPUTED TOMOGRAPHIC STUDY OF THE HEAD

Plain and post contrast studies available for review.

BREED

Standard Poodle

COMPUTED TOMOGRAPHIC FINDINGS

The brain presents no deviation from normal anatomy and symmetry. The grey and white matter distinction and the neuroparenchymal attenuation are as expected. The distribution of contrast enhancement is within normal limits throughout the parenchyma and meninges. The ventricular system is non-dilated and within the limits of the expected volume and symmetry.

SEX

Neutered Male

Thin and smoothly folded conchae and turbinates with even smooth mucosal lining. The osseous lining of the nasal cavities is intact.

AGE

6 Years

Both temporomandibular joints present congruent joint spaces with even subchondral bone surfaces and are considered within normal limits.

Both tympanic bullae are aerated, the mucosal lining is not seen, the bony wall is smooth and thin. The external auditory meatuses present within normal limits.

INTERPRETED BYNele Eley, DVM
Dr. med. Vet. DipECVDI

The submandibular and medial retropharyngeal lymph nodes are small and elongated with a normal short-to-long-axis-ratio is < 0.5 , the attenuation and contrast enhancement pattern is uniform.

The salivary glands present within normal limits.

HOSPITAL NAMEQueen Creek
Veterinary Clinic

The visible dentition is within normal limits.

COMPUTED TOMOGRAPHIC DIAGNOSIS

- Structurally normal CT study of the brain.

REFERRING VET

Dr. Makenzie Kurth

INTERPRETATION OF THE FINDINGS & FURTHER RECOMMENDATIONS

The CT study did not reveal evidence of structural brain pathology. The negative CT findings do support the potential of primary epilepsy, however, metabolic/toxic, inflammatory/infectious, neurodegenerative, and other pathology cannot be ruled out entirely and complementary csf analysis could be considered.

INVOICE

53631

DATE

8-22-22



PATIENT

Bennett Millaud

SPECIES

Canine

BREED

Standard Poodle

SEX

Neutered Male

AGE

6 Years

INTERPRETED BY

Nele Eley, DVM
Dr. med. Vet. DipECVDI

HOSPITAL NAME

Queen Creek
Veterinary Clinic

REFERRING VET

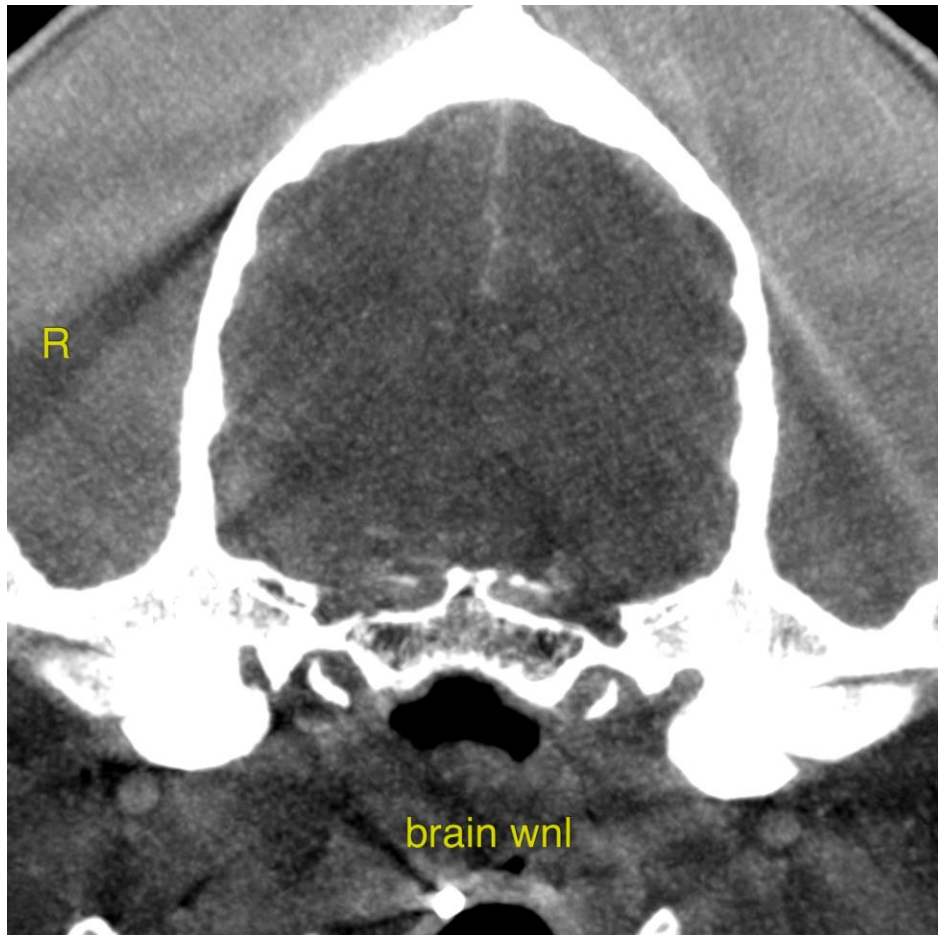
Dr. Makenzie Kurth

INVOICE

53631

DATE

8-22-22



The information and recommendations provided are based on the images presented by the referring veterinarian/sonographer. No evaluation can be communicated regarding pathology that was not visible in the image/video clips provided.

Thank you for this referral. If the clinical or image interpretation does not parallel your findings or if I can be of any further assistance please contact me.

Nele Eley, DVM, Dr. med. vet., DipECVDI
European Specialist in Veterinary Diagnostic Imaging, Cert. Radiology,
Senior lecturer University of Giessen, Germany, Veterinary Faculty, Department of Radiology
Nele.Eley@sonopath.com