



**PATIENT PRESENTING CLINICAL SIGNS**

Ted Floyd  
**SPECIES** Canine  
**BREED** French Bulldog  
**SEX** Intact Male  
**AGE** 8 Years, 7 Months

REFERENCE SONOPATH CASE #: 1688683770 August 7th, 2023: Pt was prescribed Prednisolone 5mg tab - 15 count - 1/2 tab PO Q12 for 5 days, then 1/2tab PO SID for 5 days, then 1/2 tab PO EOD - O noticed that once then began to taper the dose that he was painful. O also noticed his face began to swell again. Simplicef 100mg - 7count - 1/2 tab PO SID Gabapentin 100mg - 40 count - 1 cap PO Q8-12. O brought him in August 18th for the pain and swelling. O was doubling the Gabapentin, but only thought that it was decreasing his pain by a small amount. In clinic we gave Buprenex inj, along with sending some home for oral use. Cerenia injection to alleviate hyper salivation. 150mL Bolus of Plasma-Lyte A. Nebulization with Dexamethasone treatment. Condition improved while in the hospital for a few hours - sent home for the weekend. O reports today that he had a great weekend. eating and drinking normally. Breathing improved. Pain managed well. CT performed today for comparison.  
 Abnormal PE/Chem/CBC/UA Results: see attachment for today's blood work.

**COMPUTED TOMOGRAPHIC STUDY OF THE HEAD & NECK**

Plain and post contrast studies are available for review and compared to prior study dated 7-6-23.

**COMPUTED TOMOGRAPHIC FINDINGS**

A diagnosis of the tumor type is not provided, and I am also unaware of the type of procedure that has been performed, if at all.

The mass has increased in size significantly from measuring 3 x 2.5 x 4.5 to 5 x 4 x 5 cm. Extensive peripheral soft tissue swelling is seen. Increased contrast enhancement with a persistently nonuniform pattern and multifocal intralesional cavitation is noted. Mild progression of the osteolytic changes is seen as well.

Increased right submandibular and retropharyngeal lymph node enlargement is noted.

Stationary mediastinal lymphadenomegaly is seen.

**COMPUTED TOMOGRAPHIC DIAGNOSIS**

- Suspect progression of tumor growth and tumor extension of the mass of the right zygomatic arch.
- Mildly progressive submandibular and retropharyngeal lymphadenomegaly.
- Stationary cranial mediastinal lymphadenomegaly.
- Stationary right hand sided otitis media and periodontal disease.

**INVOICE INTERPRETATION OF THE FINDINGS & FURTHER RECOMMENDATIONS**

59825  
**DATE** 8-21-23

Based on the size measurements, progression of the tumor growth and tumor extension is suspected. Perilesional inflammation may add to the size of the tumor from a clinical perspective. Nevertheless, taking the comparison to the prior study into account, there is significant increase in the size of the enhancing mass as well.

Further enlargement of the lymph nodes may reflect hyperplasia in terms of increased resorption; however, metastatic disease remains a differential diagnosis as well.

**INTERPRETED BY**  
 Nele Eley, DVM  
 Dr. med. Vet. DipECVDI

**HOSPITAL NAME**  
 Neel Veterinary  
 Hospital

**REFERRING VET**  
 Dr. Ellen Domnick



**PATIENT**

Ted Floyd

**SPECIES**

Canine

**BREED**

French Bulldog

**SEX**

Intact Male

**AGE**

8 Years, 7 Months

**INTERPRETED BY**

Nele Eley, DVM  
Dr. med. Vet. DipECVDI

**HOSPITAL NAME**

Neel Veterinary  
Hospital

**REFERRING VET**

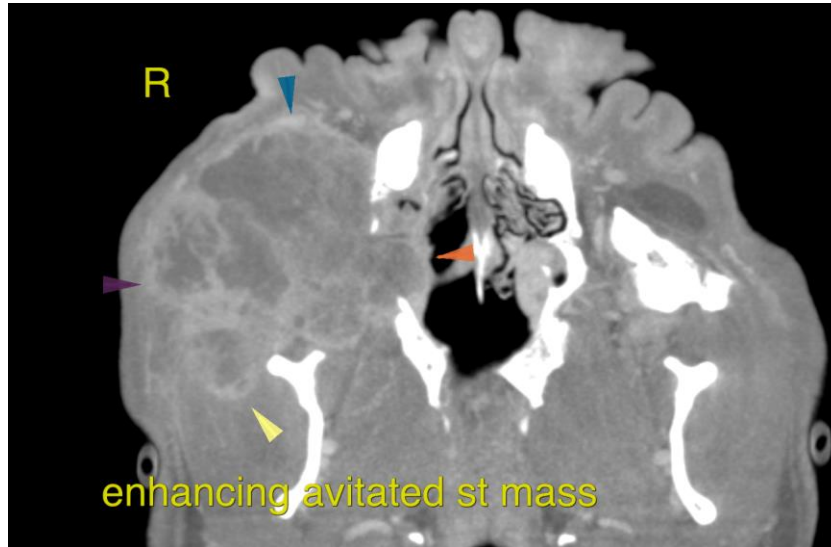
Dr. Ellen Domnick

**INVOICE**

59825

**DATE**

8-21-23



The information and recommendations provided are based on the images presented by the referring veterinarian/sonographer. No evaluation can be communicated regarding pathology that was not visible in the image/video clips provided.

Thank you for this referral. If the clinical or image interpretation does not parallel your findings or if I can be of any further assistance please contact me.

**Nele Eley**, DVM, Dr. med. vet., DipECVDI  
European Specialist in Veterinary Diagnostic Imaging, Cert. Radiology,  
Senior lecturer University of Giessen, Germany, Veterinary Faculty, Department of Radiology  
[info@sonopath.com](mailto:info@sonopath.com)