



**PATIENT**

Piper Risi

**PRESENTING CLINICAL SIGNS**

Severe abdominal pain, no vomiting, no diarrhea, still eating,  
Abnormal PE/Chem/CBC/UA Results: Severe pain palpitation of abdomen, enlarged superficial lymph node, blood work cbc indicated anemia, low platelets, mild hyper glycemia

**SPECIES**

Canine

**RADIOGRAPHIC STUDY OF THE ABDOMEN**

Right/left lateral and ventrodorsal views totaling 3 images available for review.

**BREED**

Cairn Terrier

**RADIOGRAPHIC FINDINGS**

The patient is mildly obese.

1.5 – 2 cm long wire type foreign objects are seen in the cranial and ventral abdomen.

**SEX**

Male Neutered

Mild generalized enlargement of the liver is noted.

The stomach is postprandial.

**AGE**

11 Years

Reduced serosal detail and mesenteric crowding are noted in the cranial and mid abdomen caudal to the stomach.

The small intestinal loops are turgid in appearance. No evidence of abnormal dilation, plication, or radiopaque foreign material is noted.

**INTERPRETED BY**

Nele Eley, DVM  
Dr. med. Vet. DipECVDI

Hypersegmentation of the descending colon is seen.

**RADIOGRAPHIC DIAGNOSIS**

- Reduced detail and crowding in the mid abdomen with suspect functional intestinal ileus.
- 2 metal wire type foreign objects in the cranial abdomen.

**HOSPITAL NAME**

Lakeshore Woods  
Animal Hospital

**INTERPRETATION OF THE FINDINGS & FURTHER RECOMMENDATIONS**

The potential of regional peritonitis or mesenteric mass effects in the cranial to mid abdomen should be considered based on the radiographic findings. The subtle changes of the small intestine suggest presence of reflective/functional ileus. Correlate with the laboratory values and consider abdominal ultrasound for further verification of the radiographic changes.

**REFERRING VET**

Dr. Sam Masoud

The foreign objects appear to be outside of the GI tract and usually are inert within the mesentery.

**INVOICE**

53605

**DATE**

8-21-22



**PATIENT**

Piper Risi

**SPECIES**

Canine

**BREED**

Cairn Terrier

**SEX**

Male Neutered

**AGE**

11 Years

**INTERPRETED BY**

Nele Eley, DVM  
Dr. med. Vet. DipECVDI

**HOSPITAL NAME**

Lakeshore Woods  
Animal Hospital

**REFERRING VET**

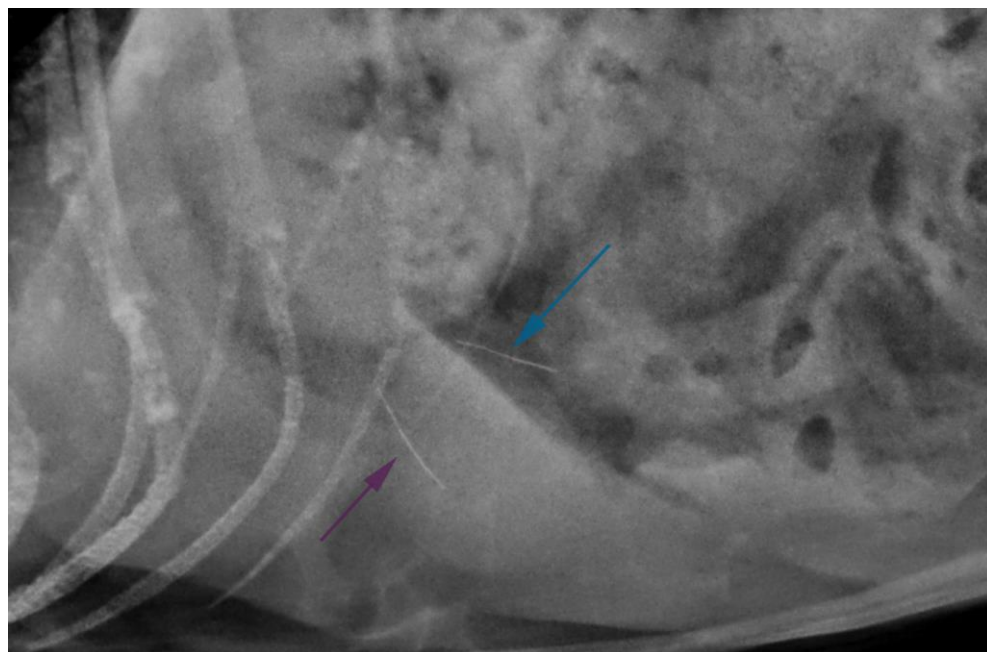
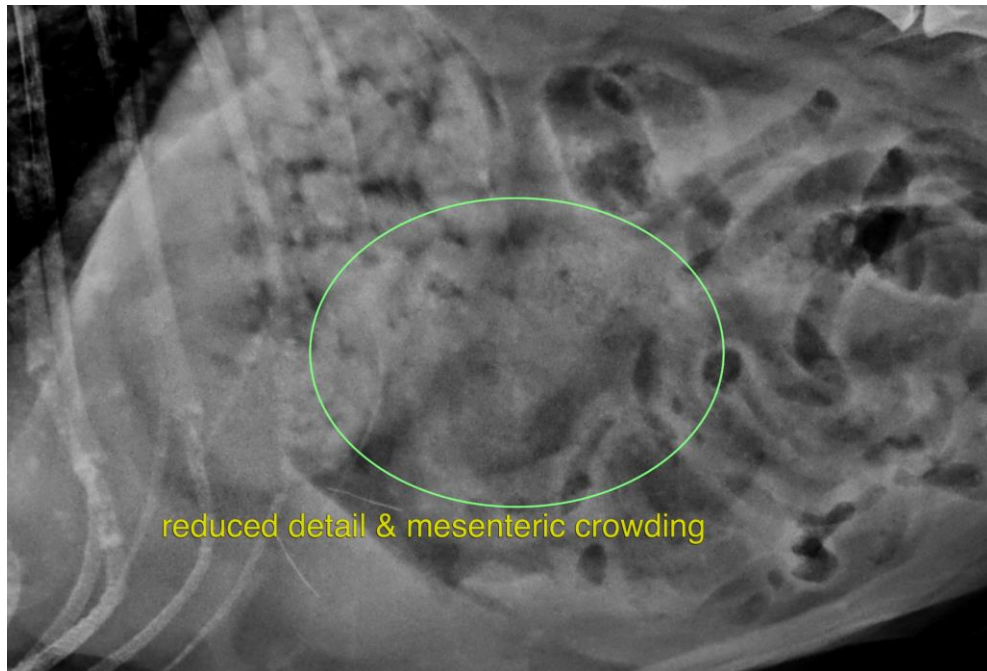
Dr. Sam Masoud

**INVOICE**

53605

**DATE**

8-21-22





**PATIENT**

Piper Risi

The information and recommendations provided are based on the images presented by the referring veterinarian/sonographer. No evaluation can be communicated regarding pathology that was not visible in the image/video clips provided.

Thank you for this referral. If the clinical or image interpretation does not parallel your findings or if I can be of any further assistance please contact me.

**SPECIES**

Canine

**Nele Eley**, DVM, Dr. med. vet., DipECVDI  
European Specialist in Veterinary Diagnostic Imaging, Cert. Radiology,  
Senior lecturer University of Giessen, Germany, Veterinary Faculty, Department of Radiology  
Nele.Eley@sonopath.com

**BREED**

Cairn Terrier

**SEX**

Male Neutered

**AGE**

11 Years

**INTERPRETED BY**

Nele Eley, DVM  
Dr. med. Vet. DipECVDI

**HOSPITAL NAME**

Lakeshore Woods  
Animal Hospital

**REFERRING VET**

Dr. Sam Masoud

**INVOICE**

53605

**DATE**

8-21-22