

**PATIENT**

Chloe Holownia

**PRESENTING CLINICAL SIGNS**

presenting complaint of back pain, intermittent in nature, for the past one week. Similar presentation approx 1 year ago. Walking with stiff gait, reluctant to jump on sofa, reluctant to walk. Painful during palpation of T12-L3. Want to R/O IVDD or other underlying cause of back pain.

**SPECIES**

Canine

**RADIOGRAPHIC STUDY OF THE THORACOLUMBAR SPINE**

Lateral and ventrodorsal views totaling 2 images available for review.

**BREED**

Maltese Mix

**RADIOGRAPHIC FINDINGS**

The intervertebral disc space width appears to be mildly reduced at T12/13 and T13/L1. The remainder of the thoracolumbar vertebrae present the expected anatomy and alignment. No evidence of aggressive bone lesions and no evidence of traumatic osseous injury is seen.

**SEX**

Female Spayed

There is mild esophageal aerophagia which is an incidental finding.

**RADIOGRAPHIC DIAGNOSIS**

- Radiographic potential for intervertebral disc disease in the thoracolumbar junction area at T12/13 and T13/L1.

**AGE**

11

**INTERPRETATION OF THE FINDINGS & FURTHER RECOMMENDATIONS**

The radiographic findings suggest potential for intervertebral disc disease at T12/13 and T13/L1. The radiographic changes may reflect uncomplicated degenerative disc disease; however, the possibility of compressive disc hernia cannot be ruled out. Depending on the severity and further development of the patient's clinical signs, cross sectional imaging could be considered for further definition, especially should this patient turn out to be a surgical candidate based on the presence of neurologic deficits.

**INTERPRETED BY**

Nele Eley, DVM  
Dr. med. Vet. DipECVDI

**HOSPITAL NAME**

River Valley  
Veterinary Wellness  
Clinic

**REFERRING VET**

Devashree Pala

**INVOICE**

47080

**DATE**

8-21-21



**PATIENT**

Chloe Holownia

**SPECIES**

Canine

**BREED**

Maltese Mix

**SEX**

Female Spayed

**AGE**

11

**INTERPRETED BY**

Nele Eley, DVM  
Dr. med. Vet. DipECVDI

**HOSPITAL NAME**

River Valley  
Veterinary Wellness  
Clinic

**REFERRING VET**

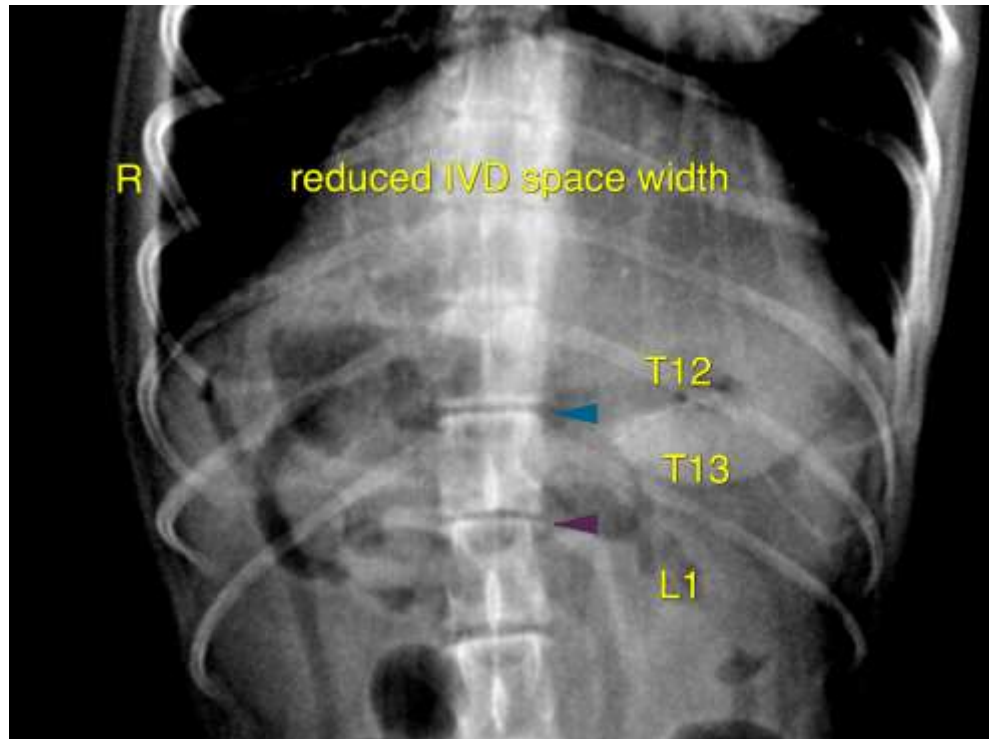
Devashree Pala

**INVOICE**

47080

**DATE**

8-21-21



The information and recommendations provided are based on the images presented by the referring veterinarian. No evaluation can be communicated regarding pathology that was not visible in the image/video clips provided.

Thank you for this referral. If the clinical or image interpretation does not parallel your findings or if I can be of any further assistance please contact me.

**Nele Eley**, DVM, Dr. med. vet., DipECVDI  
European Specialist in Veterinary Diagnostic Imaging, Cert. Radiology,  
Senior lecturer University of Giessen, Germany, Veterinary Faculty, Department of Radiology  
Nele.Eley@sonopath.com