



**PATIENT PRESENTING CLINICAL SIGNS**

Ubu Germanus Long standing Hx of dry hacking cough which recently has worsened over the past couple of weeks. Treated at another clinic with Pred and Flovent/Albuterol inhaler with no improvement. Hx of heart murmur which has also progress, O unable to pursue echo, started on Vetmedin and Sildenafil. P having hard time getting comfortable at night currently. Full list of medications include: Thyroxine 0.2mg BID, Cerenia 15-30mg daily, Gabapentin 100mg in the evening, Doxycycline 100mg daily, Sildenafil 5mg 2-3 times daily, Hydrocodone 5mg/Homatripine 1.5mg 1/2 tablet up to every 6 hours, Flurbiprofen eye drops, Vetmedin 2.5mg BID

Canine Abnormal PE/Chem/CBC/UA Results: Severe periodontal disease, overweight, cataract OS, Grade 4 L sided heart murmur, multiple dermal and SQ masses. Chem: ALP 179 H, BUN 45 H, BUN/Creat 50 H remainder all WNL and CBC WNL.

**BREED**

Jack Russel Mix

**RADIOGRAPHIC STUDY OF THE THORAX**

**SEX**

Right/left lateral and ventrodorsal views totaling 3 images available for review.

Male Neutered

**RADIOGRAPHIC FINDINGS**

The patient is obese.

**AGE**

15 Years

Multiple spondyloses and collapsed intervertebral disc spaces are seen throughout the cervical, thoracic, and thoracolumbar spine.

There is moderate bilateral shoulder osteoarthritis.

**INTERPRETED BY**

Nele Eley, DVM  
Dr. med. Vet. DipECVDI

Fat opaque subcutaneous masses are seen ventral of the sternum and within the left lateral thoracic wall.

The degree of pulmonary inflation is moderate. A moderate generalized bronchial lung pattern with multifocal cylindrical and right caudal secular bronchiectasis is seen. There also is a mild overall increase in interstitial background opacity of the lung.

**HOSPITAL NAME**

Boca Park Animal Hospital

The vertebral heart score is 12. There is mild left atrial tenting with loss of the caudal cardiac waist, however, no overt bronchial splitting is seen, and the pulmonary vasculature is thin. There is no evidence of cardiogenic pulmonary edema.

**REFERRING VET**

Hill

- Moderate left sided cardiomegaly without congestive heart failure.
- Underperfusion of the lung.
- Moderate chronic bronchial lung pattern with multifocal bronchiectasis and presumed interstitial fibrosis/scarring.
- Thoracic wall lipomas.
- Multiple spondyloses.
- Chronic intervertebral disc disease.
- Bilateral shoulder osteoarthritis.
- Obesity.

**INVOICE**

47074

**DATE**

8-20-21



**PATIENT**

Ubu Germanus

**SPECIES**

Canine

**BREED**

Jack Russel Mix

**SEX**

Male Neutered

**AGE**

15 Years

**INTERPRETED BY**

Nele Eley, DVM  
Dr. med. Vet. DipECVDI

**HOSPITAL NAME**

Boca Park Animal  
Hospital

**REFERRING VET**

Hill

**INVOICE**

47074

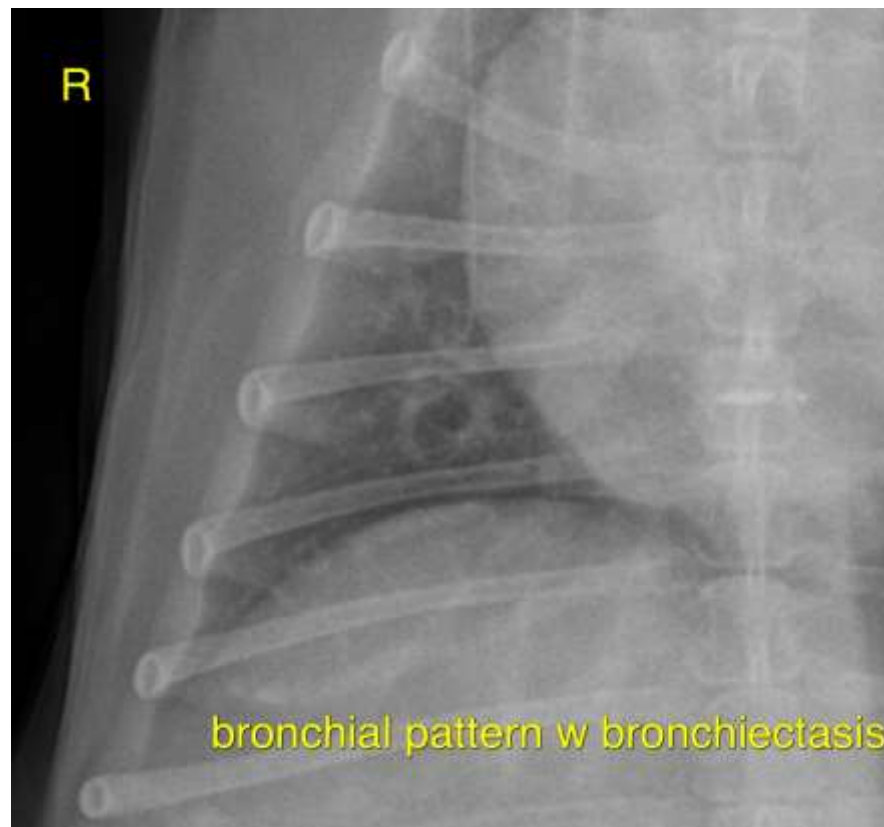
**DATE**

8-20-21

**INTERPRETATION OF THE FINDINGS & FURTHER RECOMMENDATIONS**

The main finding appears to be the moderate lower airway pattern with bronchiectasis. Consider eosinophilic bronchopneumopathy a potential. The unsatisfying response to antiallergic treatment may in part be due to the bronchiectasis which is typically associated with decreased mucociliary clearance rates which may help perpetuate the inflammation and mucus plugging. However, infectious bronchitis such as viral, bacterial, parasitic, or protozoal is a potential differential diagnosis as well. Lower airway endoscopy with airway sampling would be ideal for further definition.

There is significant left sided cardiomegaly, however, the cause of the current coughing does not appear to be cardiogenic based on the radiographic findings. There is no evidence of a mass effect of the left atrium onto the left mainstem bronchus at this point and no evidence of cardiogenic pulmonary edema is noted under the current medications.





**PATIENT**

Ubu Germanus

The information and recommendations provided are based on the images presented by the referring veterinarian. No evaluation can be communicated regarding pathology that was not visible in the image/video clips provided.

Thank you for this referral. If the clinical or image interpretation does not parallel your findings or if I can be of any further assistance please contact me.

**SPECIES**

Canine

**Nele Eley**, DVM, Dr. med. vet., DipECVDI  
European Specialist in Veterinary Diagnostic Imaging, Cert. Radiology,  
Senior lecturer University of Giessen, Germany, Veterinary Faculty, Department of Radiology  
Nele.Eley@sonopath.com

**BREED**

Jack Russel Mix

**SEX**

Male Neutered

**AGE**

15 Years

**INTERPRETED BY**

Nele Eley, DVM  
Dr. med. Vet. DipECVDI

**HOSPITAL NAME**

Boca Park Animal  
Hospital

**REFERRING VET**

Hill

**INVOICE**

47074

**DATE**

8-20-21