

**PATIENT**

Micah Hayes

PRESENTING CLINICAL SIGNS

Lethargy. Vomiting undigested food while eating blue buffalo dry food.
Abnormal PE/Chem/CBC/UA Results: DVM: SMALL INTESTINES FEEL A BIT THICKENED.
UA looked normal. Blood panel pending.

SPECIES

Feline

RADIOGRAPHIC STUDY OF THE THORAX

Right/left lateral and ventrodorsal views totaling 3 images available for review.

BREED

DMH

RADIOGRAPHIC FINDINGS

The surrounding bony structures are within normal limits.

The extrathoracic soft tissues present homogeneous without abnormalities.

SEX

MN

The heart is of normal size and shape and there is no evidence of cardiac chamber or vascular enlargement. The pulmonary vasculature is within normal limits.

AGE

3 Years, 4 Months

The cranial mediastinum presents the expected soft tissue opacity. The mediastinal width is less than twice the width of the vertebral column at the same level.

The trachea is normal in diameter and presents the anticipated course. The luminal outline of the trachea is smooth.

INTERPRETED BYNele Eley, DVM
Dr. med. Vet. DipECVDI

A moderate generalized bronchial lung pattern is noted with mild peribronchial cuffing accentuating the caudodorsal lung. The degree of pulmonary inflation is moderate.

The diaphragm is well delineated with even surface and the expected mild cranial bulging of the diaphragmatic cupola.

HOSPITAL NAMEElizabeth Animal
Hospital**RADIOGRAPHIC DIAGNOSIS**

- Moderate generalized bronchial lung pattern with mild peribronchial cuffing.

INTERPRETATION OF THE FINDINGS & FURTHER RECOMMENDATIONS

The radiographic findings are compatible with chronic lower airway disease with feline allergic lower airway syndrome being considered most likely based on the combination of the radiographic findings and the clinical history of the patient. However, infectious bronchitis such as viral, bacterial, parasitic, or protozoal cannot be ruled out entirely as a differential diagnosis.

INVOICE

47068

DATE

8-20-21



PATIENT

Micah Hayes

SPECIES

Feline

BREED

DMH

SEX

MN

AGE

3 Years, 4 Months

INTERPRETED BY

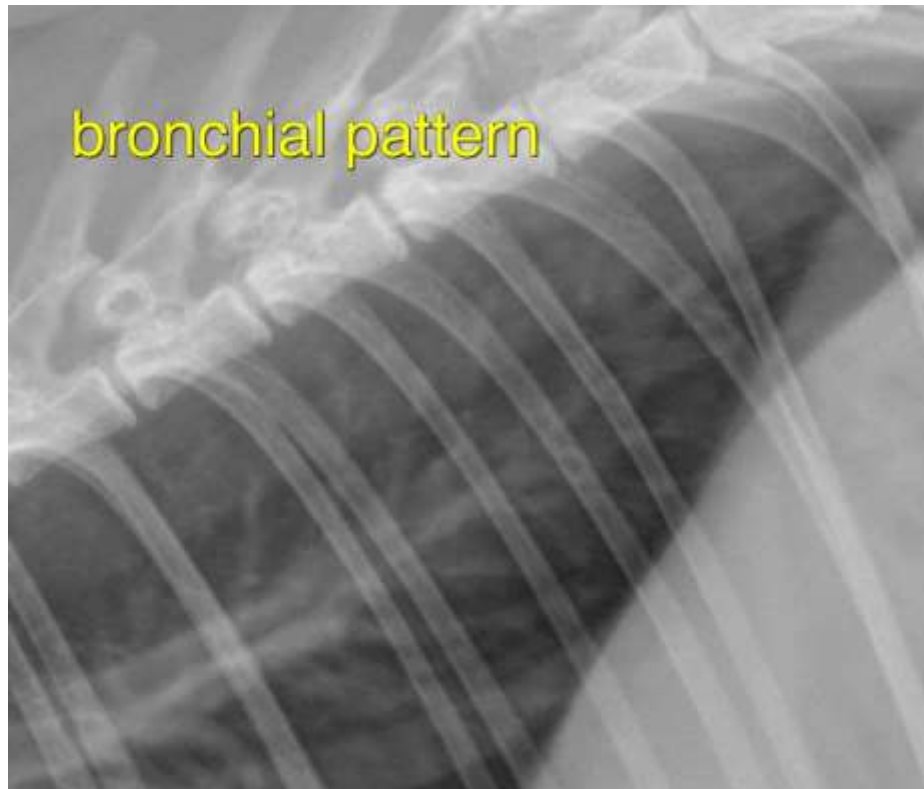
Nele Eley, DVM
Dr. med. Vet. DipECVDI

HOSPITAL NAME

Elizabeth Animal
Hospital

REFERRING VET

Leon Anderson, DVM



The information and recommendations provided are based on the images presented by the referring veterinarian. No evaluation can be communicated regarding pathology that was not visible in the image/video clips provided.

Thank you for this referral. If the clinical or image interpretation does not parallel your findings or if I can be of any further assistance please contact me.

Nele Eley, DVM, Dr. med. vet., DipECVDI
European Specialist in Veterinary Diagnostic Imaging, Cert. Radiology,
Senior lecturer University of Giessen, Germany, Veterinary Faculty, Department of Radiology
Nele.Eley@sonopath.com

INVOICE

47068

DATE

8-20-21