



**PATIENT**

Chloe Bacardi

**PRESENTING CLINICAL SIGNS**

Presented 8/13 for vomiting, abnormal cPL, T4 > 10  
 Abnormal PE/Chem/CBC/UA Results: abnormal cPL in house T4 > 10 Ref lab Total T4 > 24  
 Free T4 > 77.2

**SPECIES**

Canine

**COMPUTED TOMOGRAPHIC STUDY OF THE NECK & ABDOMEN**

Plain and post contrast studies of the neck and abdomen available for review.

**BREED**

Chihuahua

**COMPUTED TOMOGRAPHIC FINDINGS**

**Abdomen**

Mild lumbosacral stenosis is seen.

**SEX**

Female Spayed

A small soft tissue attenuating subcutaneous nodule in the right dorsal and caudal abdominal wall is seen.

Both adrenal glands present within normal limits.

**AGE**

14 Years

There is a moderate amount of mineral attenuating material within the left renal pelvis. No evidence of pyelectasia is noted. A mild amount of mineral attenuating material is present within the right renal pelvis. Occasional cortical renal cysts are seen within both kidneys.

**INTERPRETED BY**

Nele Eley, DVM  
 Dr. med. Vet. DipECVDI

The liver presents within age related normal limits. The gallbladder is moderately distended. No evidence of cystic or common bile duct dilation is noted. The extrahepatic biliary ducts are not seen.

Severe dilation of the distal jejunum and ileum with layering of gas, fluid, and solid ingesta is seen. The dilated intestinal segment contains a moderate amount of gravel. No evidence of mechanical obstacle is seen at the ileocecolic junction. The cecum and colon are empty.

**HOSPITAL NAME**

Mobile Pet Imaging

The presentation of the pancreas is within normal limits. No evidence of regional mesenteropathy is seen.

**REFERRING VET**

Meaux

The epigastric lymph nodes present within normal limits.

There is no evidence of mesenteric lymphadenomegaly.

**INVOICE**

47073

**Neck**

The C2/3 intervertebral disc space presents collapse and fusion. The C3/4 intervertebral disc space is collapsed with mild ventral spondylosis deformans.

**DATE**

8-20-21

A small 2mm sized hypoattenuating structure with focal mineralization is seen within the cranial pole of the left thyroid lobe. The right thyroid lobe presents within normal limits.

Mild collapse of the cervical trachea is seen.

**PATIENT**

Chloe Bacardi

**COMPUTED TOMOGRAPHIC DIAGNOSIS**

- Distal small intestinal ileus with gravel sign.
- Structurally normal pancreas.
- Bilateral hypercalcemic nephropathy
- Hypoattenuating nodule / cyst with metaplasia in the left lobe of the thyroid gland.
- Mild cervical tracheal collapse.
- Chronic intervertebral disc disease in the cervical spine and spondyloses.

**SPECIES**

Canine

**BREED**

Chihuahua

**SEX**

Female Spayed

**AGE**

14 Years

**INTERPRETATION OF THE FINDINGS & FURTHER RECOMMENDATIONS**

The CT findings of the pancreas are innocuous. The main finding appears to be distal small intestinal ileus with dilation of the terminal jejunum and ileum. No obvious mechanical obstruction is seen. The gravel sign, however, indicates chronically delayed emptying of the small intestine at the ileocecolic junction which may either be due to structural wall changes that may be occult on CT or functional outflow problems at the ileocecolic junction. There is no evidence of a mass, obstructive foreign material, lymphadenomegaly, or other.

The findings of the left thyroid lobe are suggestive for a small nodule or thyroid cyst which may be associated with functional nodular / adenomatous hyperplasia; however, a nonfunctional early structural change cannot be ruled out either. Early neoplasia of the thyroid appears to be a low potential based on the CT findings.

**INTERPRETED BY**Nele Eley, DVM  
Dr. med. Vet. DipECVDI**HOSPITAL NAME**

Mobile Pet Imaging

**REFERRING VET**

Meaux

**INVOICE**

47073

**DATE**

8-20-21



**PATIENT**

Chloe Bacardi

**SPECIES**

Canine

**BREED**

Chihuahua

**SEX**

Female Spayed

**AGE**

14 Years

**INTERPRETED BY**

Nele Eley, DVM  
Dr. med. Vet. DipECVDI

**HOSPITAL NAME**

Mobile Pet Imaging

**REFERRING VET**

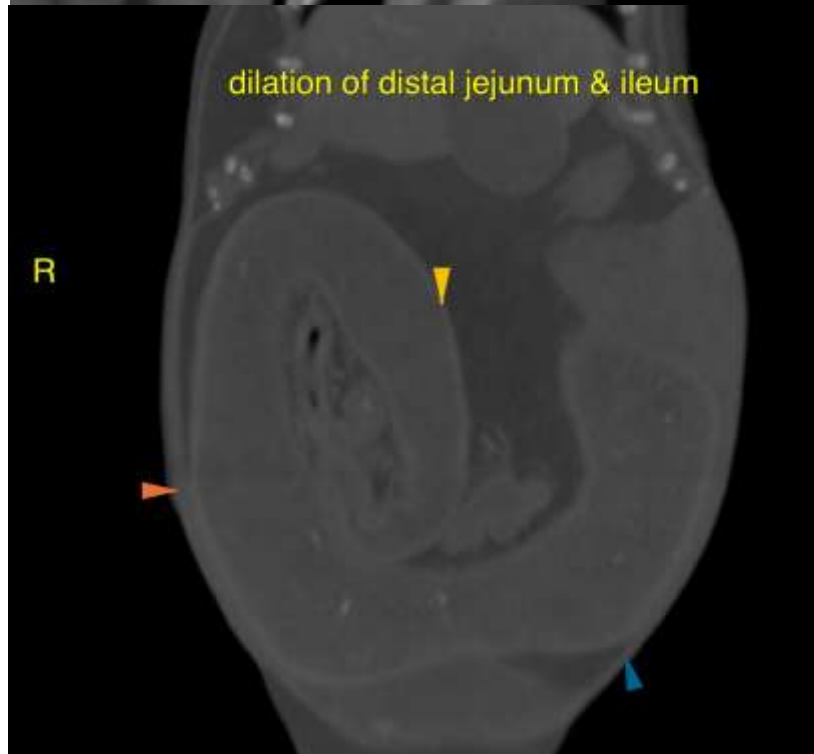
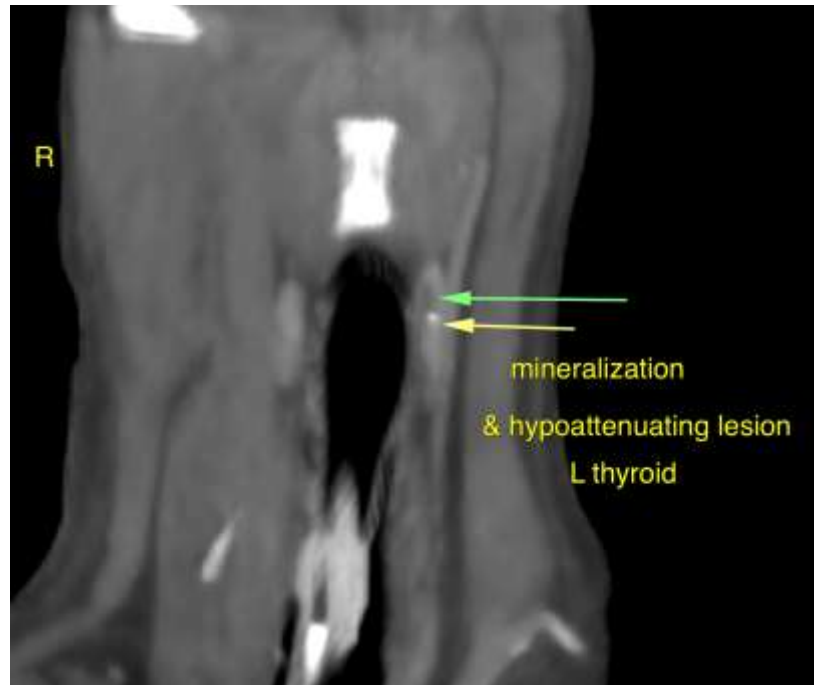Meaux

**INVOICE**

47073

**DATE**

8-20-21





**PATIENT**

Chloe Bacardi

**SPECIES**

Canine

**BREED**

Chihuahua

**SEX**

Female Spayed

**AGE**

14 Years

**INTERPRETED BY**

Nele Eley, DVM  
Dr. med. Vet. DipECVDI

**HOSPITAL NAME**

Mobile Pet Imaging

**REFERRING VET**

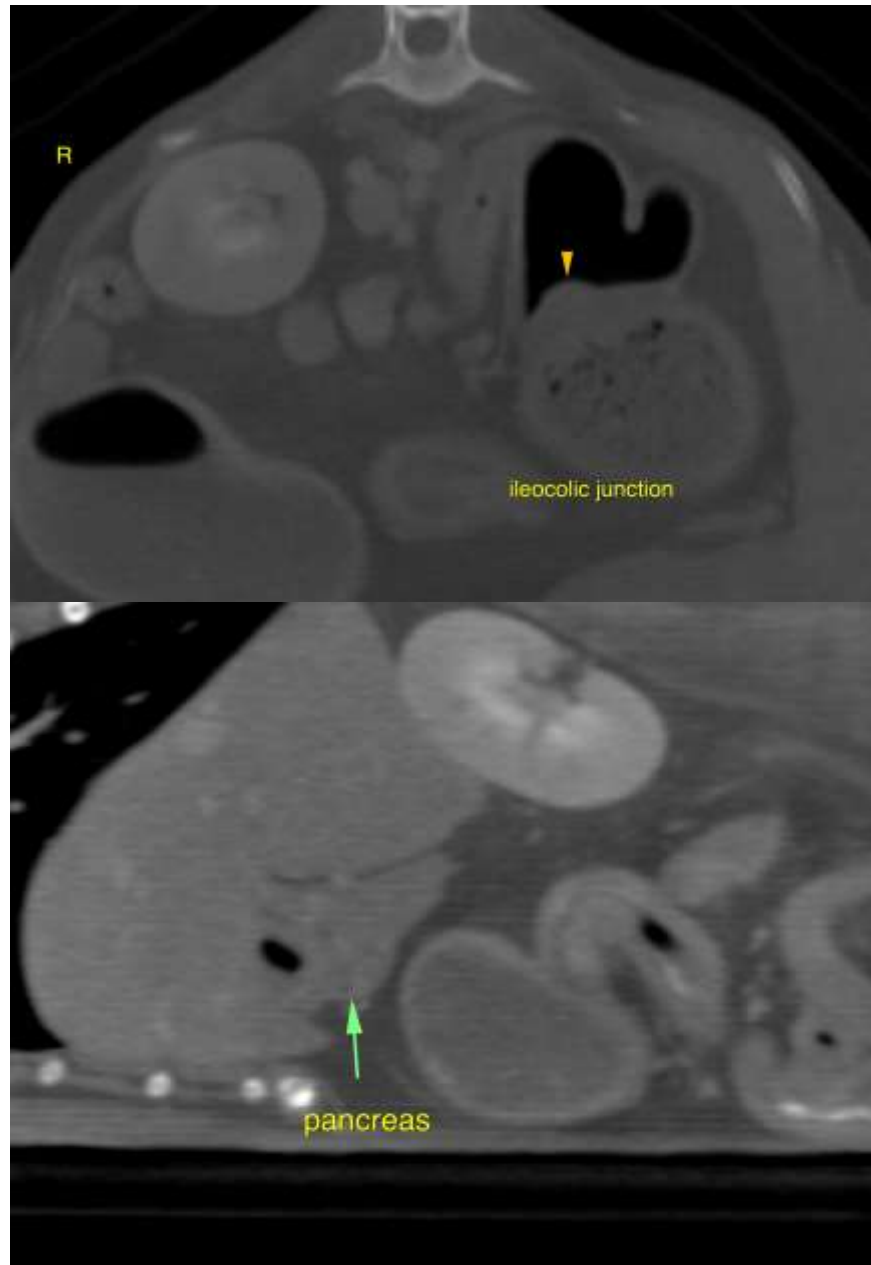
Meaux

**INVOICE**

47073

**DATE**

8-20-21





**PATIENT**

Chloe Bacardi

The information and recommendations provided are based on the images presented by the referring veterinarian. No evaluation can be communicated regarding pathology that was not visible in the image/video clips provided.

Thank you for this referral. If the clinical or image interpretation does not parallel your findings or if I can be of any further assistance please contact me.

**SPECIES**

Canine

**Nele Eley**, DVM, Dr. med. vet., DipECVDI  
European Specialist in Veterinary Diagnostic Imaging, Cert. Radiology,  
Senior lecturer University of Giessen, Germany, Veterinary Faculty, Department of Radiology  
Nele.Eley@sonopath.com

**BREED**

Chihuahua

**SEX**

Female Spayed

**AGE**

14 Years

**INTERPRETED BY**

Nele Eley, DVM  
Dr. med. Vet. DipECVDI

**HOSPITAL NAME**

Mobile Pet Imaging

**REFERRING VET**

Meaux

**INVOICE**

47073

**DATE**

8-20-21