



**PATIENT PRESENTING CLINICAL SIGNS**

Jack Stephens vomiting, bright yellow bile, very tender in his belly , Very uncomfortable. Hasn't eaten since 6pm last night  
 Abnormal PE/Chem/CBC/UA Results: cPL is positive Elevation in TCHO., ALP, GGT, TBIL, and low in CI CBC: Elevation in HGB, MCH, MCHC, and NEU%

**SPECIES**

Canine

**RADIOGRAPHIC STUDY OF THE THORAX & ABDOMEN**

Right/left lateral and ventrodorsal whole body views totaling 3 images available for review.

**BREED**

Chihuahua

**RADIOGRAPHIC FINDINGS**

**Thorax**

Redundancy of the trachea with acute dorsal kinking is noted in the cranial thorax. There is no associated mediastinal mass effect.

**SEX**

Male Neuter

The cardiac silhouette is upright and thin. The caudal vena cava and pulmonary vasculature is thin as well. No particular chamber enlargement of the heart is noted.

**AGE**

8 Years

The lung presents within age related normal limits.

**Abdomen**

**INTERPRETED BY**

Nele Eley, DVM  
 Dr. med. Vet. DipECVDI

The abdominal serosal detail appears to be reduced in the center of the abdomen which is accentuated in the region caudal to the stomach. There appears to be a mild mass effect deviating the stomach cranially.

Turgid appearance of the nondilated small intestinal loops is noted.

**HOSPITAL NAME**

St. Catherine's Animal Hospital

Note the presence of at least unilateral patella luxation and bilateral hip dysplasia.

**RADIOGRAPHIC DIAGNOSIS**

- Suspect cranial abdominal mesenteropathy with reduced serosal detail.
- Hypovolemia with microcardia and underperfusion of the lung.
- Redundant thoracic trachea – incidental finding.

**REFERRING VET**

Dr. Masoud

**INTERPRETATION OF THE FINDINGS & FURTHER RECOMMENDATIONS**

The radiographic study suggests potential for presence of mesenteric inflammation or effusion. The changes are accentuated in the cranial abdomen. Consider pancreatopathy, pathology of the biliary system, gastropathy, and other primary differential diagnoses. Further definition by means of abdominal ultrasound is strongly recommended if not performed already.

**INVOICE**

53222

**DATE**

8-2-22



**PATIENT**

Jack Stephens

**SPECIES**

Canine

**BREED**

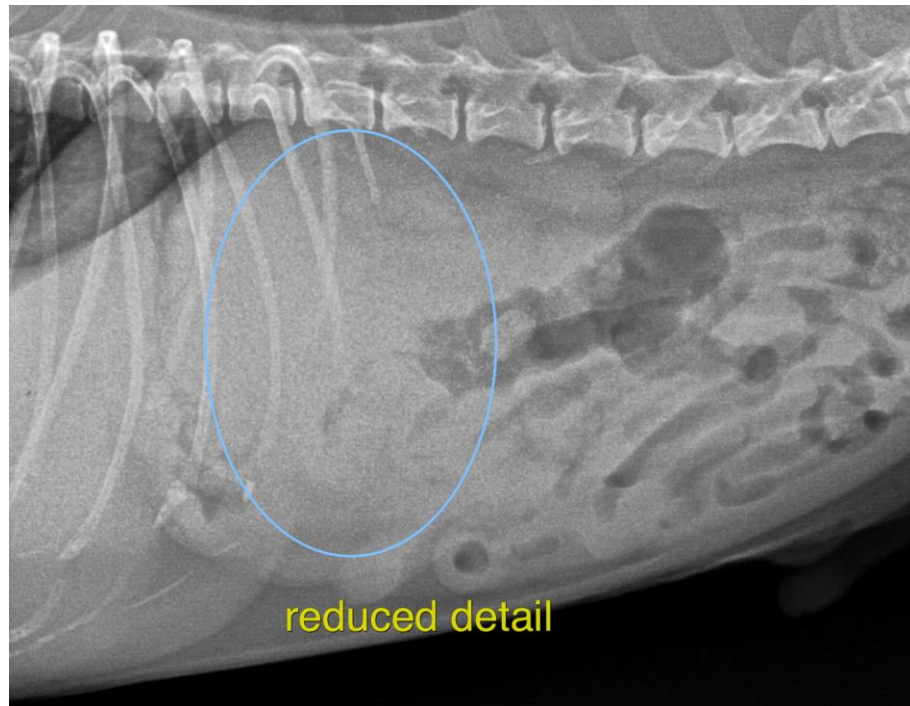
Chihuahua

**SEX**

Male Neuter

**AGE**

8 Years



**INTERPRETED BY**

Nele Eley, DVM  
Dr. med. Vet. DipECVDI

The information and recommendations provided are based on the images presented by the referring veterinarian/sonographer. No evaluation can be communicated regarding pathology that was not visible in the image/video clips provided.

Thank you for this referral. If the clinical or image interpretation does not parallel your findings or if I can be of any further assistance please contact me.

**HOSPITAL NAME**

St. Catherine's Animal  
Hospital

**Nele Eley**, DVM, Dr. med. vet., DipECVDI  
European Specialist in Veterinary Diagnostic Imaging, Cert. Radiology,  
Senior lecturer University of Giessen, Germany, Veterinary Faculty, Department of Radiology  
Nele.Eley@sonopath.com

**REFERRING VET**

Dr. Masoud

**INVOICE**

53222

**DATE**

8-2-22