



PATIENT

Hendrix Amico

PRESENTING CLINICAL SIGNS

acute injury outside- o didn't see exactly what happened- just heard the screaming - holding up rh
Abnormal PE/Chem/CBC/UA Results: rh lameness - toe touching - can apply pressure- no
severe soft tissue swelling pain on stifle palpation xrays - tibial tuberosity avulsion? sx repair vs
med management?

SPECIES

Canine

RADIOGRAPHIC STUDY OF THE RIGHT STIFLE

2 mediolateral views of the right stifle available for review.

BREED

French Bulldog

RADIOGRAPHIC FINDINGS

Extensive soft tissue swelling is noted level with the distal half of the patella tendon and its
attachment to the tibial tuberosity. Cranial displacement and cranial rotation of the tibial
tuberosity are seen with significant widening of the apophyseal growth plate.

SEX

Male

The cranial aspect of the proximal tibial epiphysis appears to be lifted as well.

Mild proximalization of the patella is seen.

AGE

5 Months

Only one fabella is visible.

RADIOGRAPHIC DIAGNOSIS

- Avulsion fracture of the right tibial tuberosity.
- Suspect Salter Harris type 1 or 2 fracture of the right proximal tibial epiphysis.

INTERPRETED BY

Nele Eley, DVM
Dr. med. Vet. DipECVDI

INTERPRETATION OF THE FINDINGS & FURTHER RECOMMENDATIONS

The radiographic study reveals tibial tuberosity apophyseal lysis in the right hind limb.
Concurrent patella tendon injury cannot be ruled out.

HOSPITAL NAME

Legacy Animal
Hospital

There is a mild patella alta.

The findings furthermore suggest the presence of concurrent Salter Harris fracture of the
proximal tibial epiphysis which appears to be lifted cranially.

REFERRING VET

Dr. Kristin Potenzzone
DVM

Open reduction and internal fixation is strongly recommended.

Only one fabella is seen in this radiographic study in the right stifle which may represent an
anatomic variant as it appears to be the same in the left hind limb. However, superimposition with
other osseous structures in this anatomic region cannot be ruled out.

INVOICE

53227

DATE

8-2-22



PATIENT

Hendrix Amico

SPECIES

Canine

BREED

French Bulldog

SEX

Male

AGE

5 Months

INTERPRETED BY

Nele Eley, DVM
Dr. med. Vet. DipECVDI

HOSPITAL NAME

Legacy Animal
Hospital

REFERRING VET

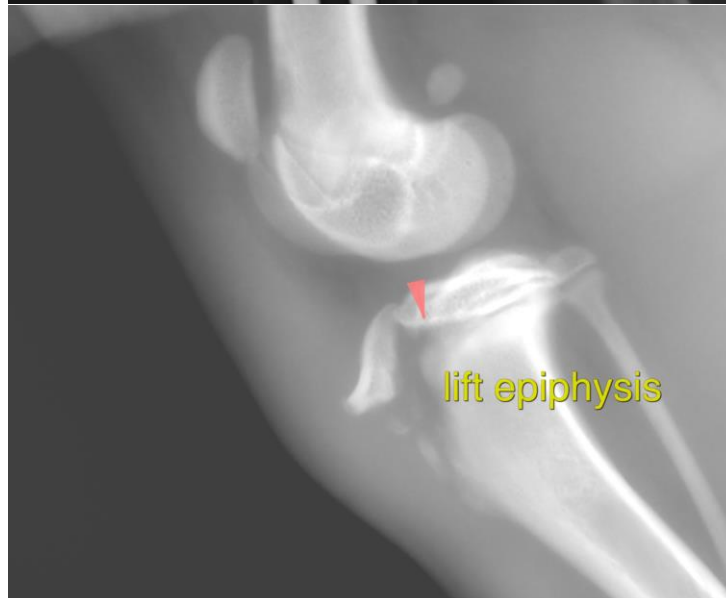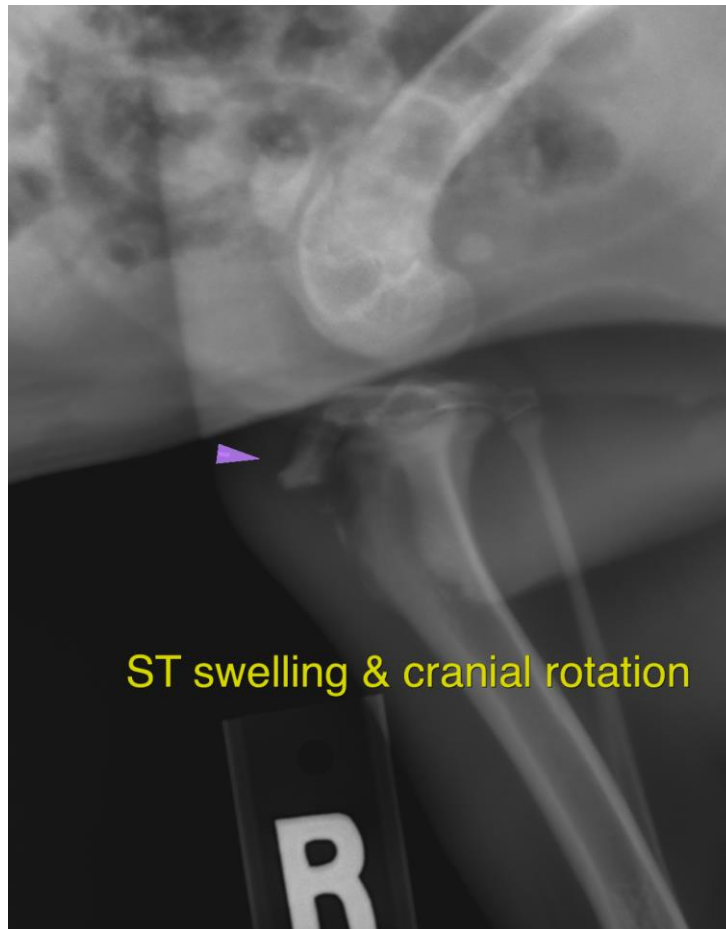
Dr. Kristin Potenzzone
DVM

INVOICE

53227

DATE

8-2-22





PATIENT

Hendrix Amico

The information and recommendations provided are based on the images presented by the referring veterinarian/sonographer. No evaluation can be communicated regarding pathology that was not visible in the image/video clips provided.

SPECIES

Canine

Thank you for this referral. If the clinical or image interpretation does not parallel your findings or if I can be of any further assistance please contact me.

BREED

French Bulldog

Nele Eley, DVM, Dr. med. vet., DipECVDI
European Specialist in Veterinary Diagnostic Imaging, Cert. Radiology,
Senior lecturer University of Giessen, Germany, Veterinary Faculty, Department of Radiology
Nele.Eley@sonopath.com

SEX

Male

AGE

5 Months

INTERPRETED BY

Nele Eley, DVM
Dr. med. Vet. DipECVDI

HOSPITAL NAME

Legacy Animal
Hospital

REFERRING VET

Dr. Kristin Potenzzone
DVM

INVOICE

53227

DATE

8-2-22