



PATIENT

Buster Mann

PRESENTING CLINICAL SIGNS

Referred for surgical consult regarding possible anal sac tumor. Noted to have soft fluctuant mass on left side of anus for a few weeks with no issues. 7-30 started straining to defecate and scooting. Around same time mass became firm. 8-2 'mass' ruptured, patient brought in for evaluation. FNA performed by rDVM on 7-31.

SPECIES

Canine

COMPUTED TOMOGRAPHIC STUDY OF THE THORAX & ABDOMEN

Plain and post contrast studies in soft tissue and bone windows available for review.

BREED

Dachshund

COMPUTED TOMOGRAPHIC FINDINGS

Patient has a history of prior left sided hemilaminectomy between L3/4 and L4/5.

SEX

Generalized muscle wasting is noted.

MN

Diffuse left sided swelling of the perineal area with fat stranding is seen. The left anal sac wall is collapsed with a defect in the lateral wall and infiltration of fluid attenuating material. No soft tissue mass can be seen. The right anal sac is moderately distended with fluid attenuating material.

AGE

15 Years

The regional lymph nodes present within normal limits.

Small dermal nodules are seen in the flank.

INTERPRETED BY

Nele Eley, DVM
Dr. med. Vet. DipECVDI

Both kidneys present multiple cortical renal cysts.

Multiple hyperenhancing splenic nodules are seen.

HOSPITAL NAME

Bluegrass Veterinary
Specialists

There is moderate generalized hepatomegaly with multiple nodules of varying size and enhancement. The hepatic nodules are distributed throughout all liver lobes and measure up to 2.5 cm in diameter.

Mild gallbladder wall enhancement is noted. The common bile duct presents mild generalized dilation with no evidence of obstruction.

REFERRING VET

Guevara

The pancreas presents within normal limits.

The adrenal glands present within normal limits.

INVOICE

53225

Thorax

The lung and bronchial tree are within normal limits.

There is no evidence of mediastinal lymphadenomegaly.

DATE

8-2-22

No evidence of cardiovascular pathology is noted.



PATIENT

Buster Mann

SPECIES

Canine

BREED

Dachshund

SEX

MN

AGE

15 Years

INTERPRETED BY

Nele Eley, DVM
Dr. med. Vet. DipECVDI

HOSPITAL NAME

Bluegrass Veterinary
Specialists

REFERRING VET

Guevara

INVOICE

53225

DATE

8-2-22

COMPUTED TOMOGRAPHIC DIAGNOSIS

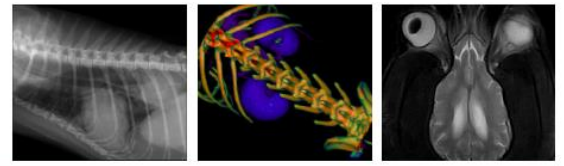
- Ruptured left anal sac with extensive peripheral cellulitis.
- No evidence of regional lymphadenomegaly.
- Hepatomegaly with multiple nodules.
- Multiple splenic nodules.
- Multiple small cortical renal cysts in both kidneys.
- Suspect cholecystitis.

INTERPRETATION OF THE FINDINGS & FURTHER RECOMMENDATIONS

A discrete soft tissue mass is not seen in the left anal sac. Left anal sac abscessation and rupture are the most likely differential diagnoses based on the CT presentation. However, neoplasia with tumoral necrosis cannot be ruled out entirely as a differential diagnosis. Note the presence of extensive peripheral cellulitis in the perineum. No evidence of concurrent sublumbar lymphadenomegaly is noted.

Differential diagnosis for the hepatic changes includes benign nodular hyperplasia as well as endocrine and metabolic hepatopathy or hepatitis. Secondary neoplasia of the liver cannot be ruled out entirely but is thought less likely. Consider parenchymal sampling for further definition as well as correlation with the laboratory values.

The splenic nodules are likely to represent benign nodular hyperplasia or extramedullary hematopoiesis. A secondary splenic neoplasia is thought unlikely but can never be ruled out entirely.



PATIENT

Buster Mann

SPECIES

Canine

BREED

Dachshund

SEX

MN

AGE

15 Years

INTERPRETED BY

Nele Eley, DVM
Dr. med. Vet. DipECVDI

HOSPITAL NAME

Bluegrass Veterinary
Specialists

REFERRING VET

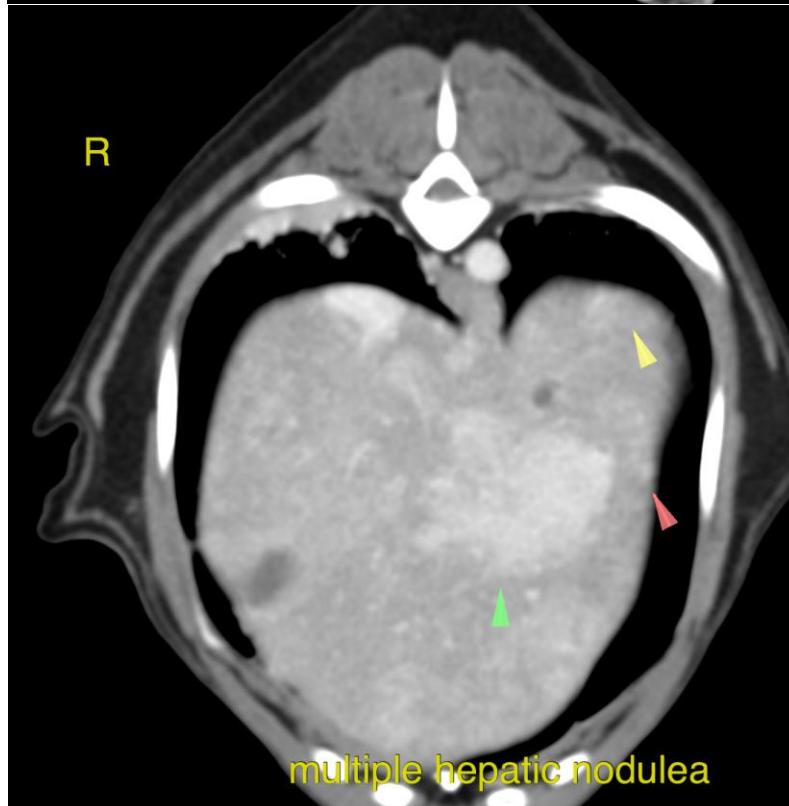
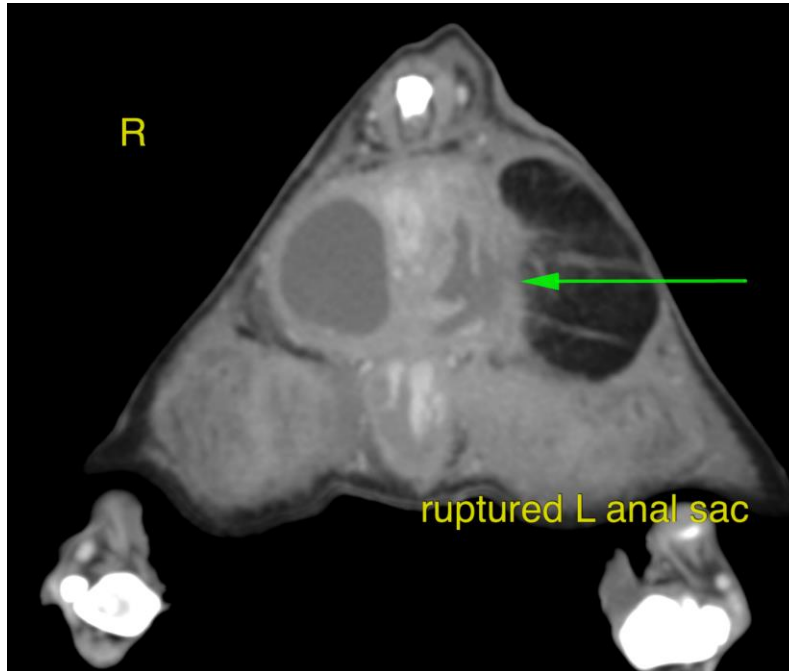
Guevara

INVOICE

53225

DATE

8-2-22





PATIENT

Buster Mann

The information and recommendations provided are based on the images presented by the referring veterinarian/sonographer. No evaluation can be communicated regarding pathology that was not visible in the image/video clips provided.

SPECIES

Canine

Thank you for this referral. If the clinical or image interpretation does not parallel your findings or if I can be of any further assistance please contact me.

BREED

Dachshund

Nele Eley, DVM, Dr. med. vet., DipECVDI
European Specialist in Veterinary Diagnostic Imaging, Cert. Radiology,
Senior lecturer University of Giessen, Germany, Veterinary Faculty, Department of Radiology
Nele.Eley@sonopath.com

SEX

MN

AGE

15 Years

INTERPRETED BY

Nele Eley, DVM
Dr. med. Vet. DipECVDI

HOSPITAL NAME

Bluegrass Veterinary
Specialists

REFERRING VET

Guevara

INVOICE

53225

DATE

8-2-22