



**PATIENT PRESENTING CLINICAL SIGNS**

Maui Irizarry  
 He lost 12 pounds since 7/21. He hasn't eaten in the last 4 days. He has thrown up a few times. He has been throwing up dark colored bile with mucous. Noticed 3 days ago that he wasn't feeling good. He likes to eat socks. He did eat two socks and then threw them up about 3 days ago. The next day he was sluggish. Still drinking water but not eating. Yesterday drank some and still didn't eat.

**SPECIES**

Canine  
 Abnormal PE/Chem/CBC/UA Results: SLIGHT DEHYDRATION EMPTY CAUDAL ABDOMEN POSSIBLE MASS/FOREIGN BODY IN CRANIAL ABDOMEN DISCOMFORT TO ABDOMINAL PALPATION HUNCHED APPEARANCE TO ABDOMEN

**BREED**

Goldendoodle

**RADIOGRAPHIC STUDY OF THE ABDOMEN**

Right/left lateral and ventrodorsal views totaling 5 images available for review.

**SEX**

MN

**RADIOGRAPHIC FINDINGS**

The radiographic study of the abdomen reveals multiple dilated small intestinal loops. Multiple of the dilated loops contain mainly gas. One of the dilated loops however contains soft tissue opaque layered material mixed with gas and appears to be situated in the right caudal abdomen on the orthogonal views.

**AGE**

1 Year, 8 Months

No evidence of foreign material within the stomach is seen.

The colon contains gas and a mild amount of inspissated fecal matter.

**INTERPRETED BY**

Nele Eley, DVM  
 Dr. med. Vet. DipECVDI

The abdominal serosal detail appears maintained.

**RADIOGRAPHIC DIAGNOSIS**

- Suspect mechanical ileus with foreign material.

**HOSPITAL NAME**

Elizabeth Animal Hospital

**INTERPRETATION OF THE FINDINGS & FURTHER RECOMMENDATIONS**

The radiographic study suggests mechanical obstruction of the small intestine with foreign material. The radiographic findings at the time prompt an indication for surgical exploration. However, significant time has elapsed since obtaining the radiographs and some foreign material can actually pass with proper rehydration, prokinetics, and other. I would strongly recommend to either perform an abdominal ultrasound or repeat the radiographs prior to planning any surgical intervention.

**REFERRING VET**

Kim Allyn, DVM

**INVOICE**

53593

**DATE**

8-19-22



**PATIENT**

Maui Irizarry

**SPECIES**

Canine

**BREED**

Goldendoodle

**SEX**

MN

**AGE**

1 Year, 8 Months

**INTERPRETED BY**

Nele Eley, DVM  
Dr. med. Vet. DipECVDI

**HOSPITAL NAME**

Elizabeth Animal  
Hospital

**REFERRING VET**

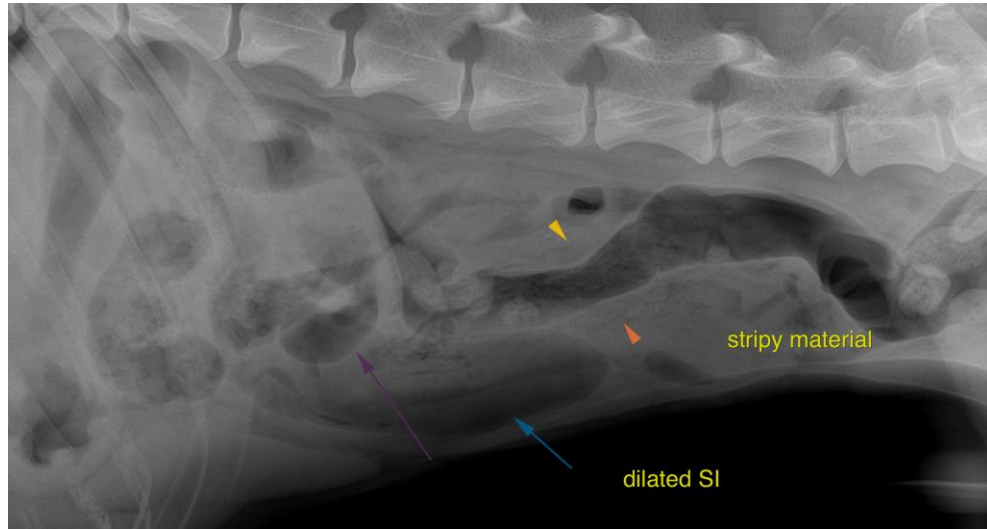
Kim Allyn, DVM

**INVOICE**

53593

**DATE**

8-19-22



The information and recommendations provided are based on the images presented by the referring veterinarian/sonographer. No evaluation can be communicated regarding pathology that was not visible in the image/video clips provided.

Thank you for this referral. If the clinical or image interpretation does not parallel your findings or if I can be of any further assistance please contact me.

**Nele Eley**, DVM, Dr. med. vet., DipECVDI  
European Specialist in Veterinary Diagnostic Imaging, Cert. Radiology,  
Senior lecturer University of Giessen, Germany, Veterinary Faculty, Department of Radiology  
Nele.Eley@sonopath.com