

**PATIENT**

Moose Welch

PRESENTING CLINICAL SIGNS

This is a follow-up ultrasound of the left Achilles tendon to assess healing post surgical repair. The last ultrasound was performed June 7, 2023 and assessed by Dr. Eley. The patient has been doing well with rehab and has been wearing a brace. We are getting to the point where we are considering removing the brace.

SPECIES

Canine

ULTRASONOGRAPHIC STUDY OF THE LEFT ACHILLES TENDON

Findings are compared to prior report dated 6-7-23.

BREED

German Shep Mix

ULTRASONOGRAPHIC FINDINGS**Left Achilles Tendon****SEX**

The patient has a history of gastrocnemius tendon rupture and repair in January 2023.

MN

Uniformly hyperechoic fibers of moderate and long length are seen bridging the original defect within the tendon. The areas of reduced echogenicity have resolved and disappeared. The suture material is in situ and within normal limits. There appear to be fibers and tissue crossing between the superficial and deep layers of the tendon with reduced motion between the superficial and deep components. The overall thickness of the injured tendon has reduced compared with the prior study.

AGE

2 Years

ULTRASONOGRAPHIC DIAGNOSIS**INTERPRETED BY**

Nele Eley, DVM
Dr. med. Vet. DipECVDI

- Recheck 8 months after complex left achilles tendon injury with tendon suture in January 2023.
- Progressive healing of the left achilles tendon with uniform fiber texture of at least moderate length.

HOSPITAL NAME

Mountain Vista
Veterinary Hospital

INTERPRETATION OF THE FINDINGS & FURTHER RECOMMENDATIONS

The ultrasonographic study shows further progression of the healing of the complex left achilles tendon injury. The original defect is now bridged by uniformly textured replacement tissue with fibers of moderate to long length. The remodeling of the tendon has progressed as well. No evidence of complications or a new injury is seen. Relative biomechanical stability can be assumed and resumption of loading and exercise appears to be feasible.

REFERRING VET

Dr. Jacquie Pankatz

INVOICE

59810

DATE

8-18-23



PATIENT

Moose Welch

SPECIES

Canine

BREED

German Shep Mix

SEX

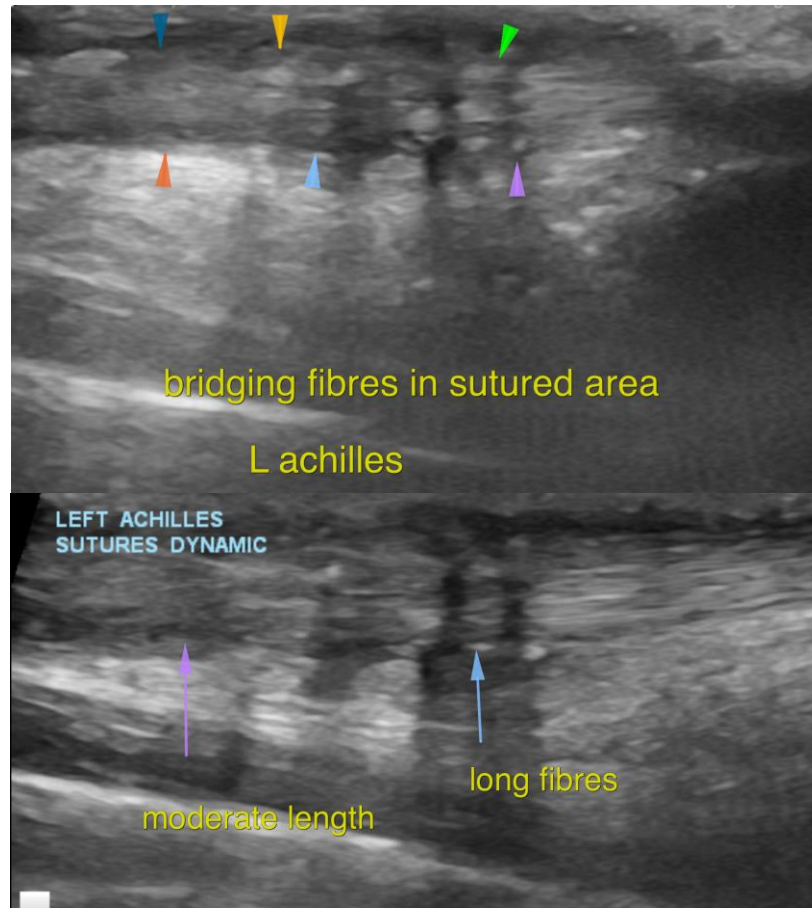
MN

AGE

2 Years

INTERPRETED BY

Nele Eley, DVM
Dr. med. Vet. DipECVDI



HOSPITAL NAME

Mountain Vista
Veterinary Hospital

REFERRING VET

Dr. Jacque Pankatz

INVOICE

59810

DATE

8-18-23

The information and recommendations provided are based on the images presented by the referring veterinarian/sonographer. No evaluation can be communicated regarding pathology that was not visible in the image/video clips provided.

Thank you for this referral. If the clinical or image interpretation does not parallel your findings or if I can be of any further assistance please contact me.

Nele Eley, DVM, Dr. med. vet., DipECVDI
European Specialist in Veterinary Diagnostic Imaging, Cert. Radiology,
Senior lecturer University of Giessen, Germany, Veterinary Faculty, Department of Radiology
info@sonopath.com