

**PATIENT**

Tucker Franke

PRESENTING CLINICAL SIGNS

coughing

SPECIES

Feline

RADIOGRAPHIC STUDY OF THE THORAX & ABDOMEN

Single right lateral whole body view available for review.

BREED

DSH

Thorax

Mild mid thoracic spondyloses are seen at T8/9 and T9/10 and considered unrelated to the reason of clinical presentation.

SEX

Male/neutered

The degree of pulmonary inflation is deep. The chest is expanded. A moderate generalized bronchial lung pattern is seen and evenly distributed throughout the lung.

Mild esophageal aerophagia is seen.

AGE

15 Years

There is no radiographic evidence of cardiovascular pathology.

Course and width of the trachea are considered within normal limits.

INTERPRETED BYNele Eley, DVM
Dr. med. Vet. DipECVDI**Abdomen**

There is mild spondylosis within the lumbar spine at L1/2, L2/3, L3/4, L5/6, and L7/S1.

The abdominal serosal detail is within normal limits.

HOSPITAL NAMENew Bridge
Veterinary Practice

Moderate gastrointestinal aerophagia is noted. No evidence of abnormal content is seen within the stomach and there is no evidence of gastric or intestinal dilation seen.

RADIOGRAPHIC DIAGNOSIS

- Moderate generalized chronic lower airway pattern with air trapping.
- Gastrointestinal aerophagia - no other evidence of structural gastrointestinal pathology.
- Multiple spondyloses.

REFERRING VET

Dr. Abina Glennon

INTERPRETATION OF THE FINDINGS & FURTHER RECOMMENDATIONS**INVOICE**

47017

The radiographic findings strongly support the potential of recurrent allergic feline lower airway syndrome/feline asthma. Infectious bronchitis such as viral, bacterial, parasitic, or protozoal cannot be ruled out entirely as a differential diagnosis.

There is no evidence of gastrointestinal ileus based on the radiographic findings.

DATE

8-18-21



PATIENT

Tucker Franke

SPECIES

Feline

BREED

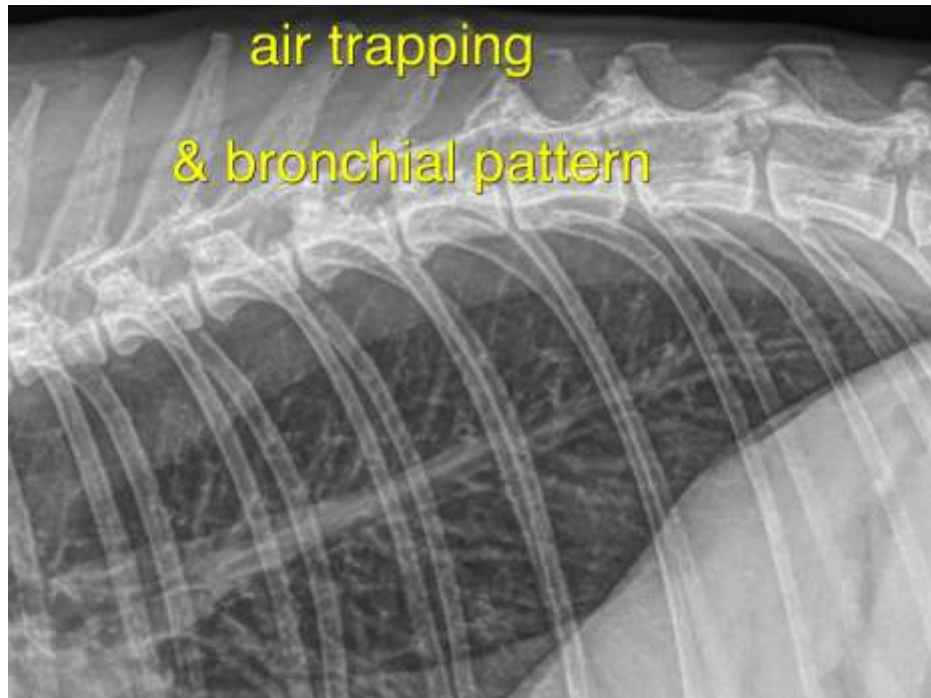
DSH

SEX

Male/neutered

AGE

15 Years



INTERPRETED BY

Nele Eley, DVM
Dr. med. Vet. DipECVDI

The information and recommendations provided are based on the images presented by the referring veterinarian. No evaluation can be communicated regarding pathology that was not visible in the image/video clips provided.

HOSPITAL NAME

New Bridge
Veterinary Practice

Thank you for this referral. If the clinical or image interpretation does not parallel your findings or if I can be of any further assistance please contact me.

Nele Eley, DVM, Dr. med. vet., DipECVDI
European Specialist in Veterinary Diagnostic Imaging, Cert. Radiology,
Senior lecturer University of Giessen, Germany, Veterinary Faculty, Department of Radiology
Nele.Eley@sonopath.com

REFERRING VET

Dr. Abina Glennon

INVOICE

47017

DATE

8-18-21