



PATIENT

Parker Farewege

PRESENTING CLINICAL SIGNS

acute onset of hind left leg pain

SPECIES

Canine

RADIOGRAPHIC STUDY OF THE LEFT STIFLE

Mediolateral view of the left stifle, craniocaudal views of both stifles on ventrodorsal hip extended radiograph totaling 2 images available for review.

BREED

Maltese

RADIOGRAPHIC FINDINGS

Bilateral medial patella luxation is seen.

The muscle volume appears symmetric in both hind limbs.

The coxofemoral joints present within normal limits.

SEX

MN

Moderate osteoarthritic changes and moderate articular swelling of the left stifle are seen.

AGE

5

The medial fabella is small and in a distal position which is a common incidental finding in chondrodystrophic breeds.

There appears to be medial curvature of the proximal tibia which, however, may be influenced by the limb positioning/pronation.

INTERPRETED BY

Nele Eley, DVM
Dr. med. Vet. DipECVDI

RADIOGRAPHIC DIAGNOSIS

- Bilateral medial patella luxation with moderate left stifle osteoarthritis.

INTERPRETATION OF THE FINDINGS & FURTHER RECOMMENDATIONS

The radiographic study reveals moderate osteoarthritis of the left stifle joint with medial patella luxation. Medial patella luxation of the right stifle joint is seen as well. Concurrent cranial cruciate ligament injury should be ruled out by means of clinical palpation. Consider surgical intervention and the potential for mild angular limb deformity of the proximal tibia. No concurrent coxofemoral dysplasia is seen.

HOSPITAL NAME

Rockaway Animal
Hospital

REFERRING VET

Dr. Maniar

INVOICE

47025

DATE

8-18-21



PATIENT

Parker Farewege

SPECIES

Canine

BREED

Maltese

SEX

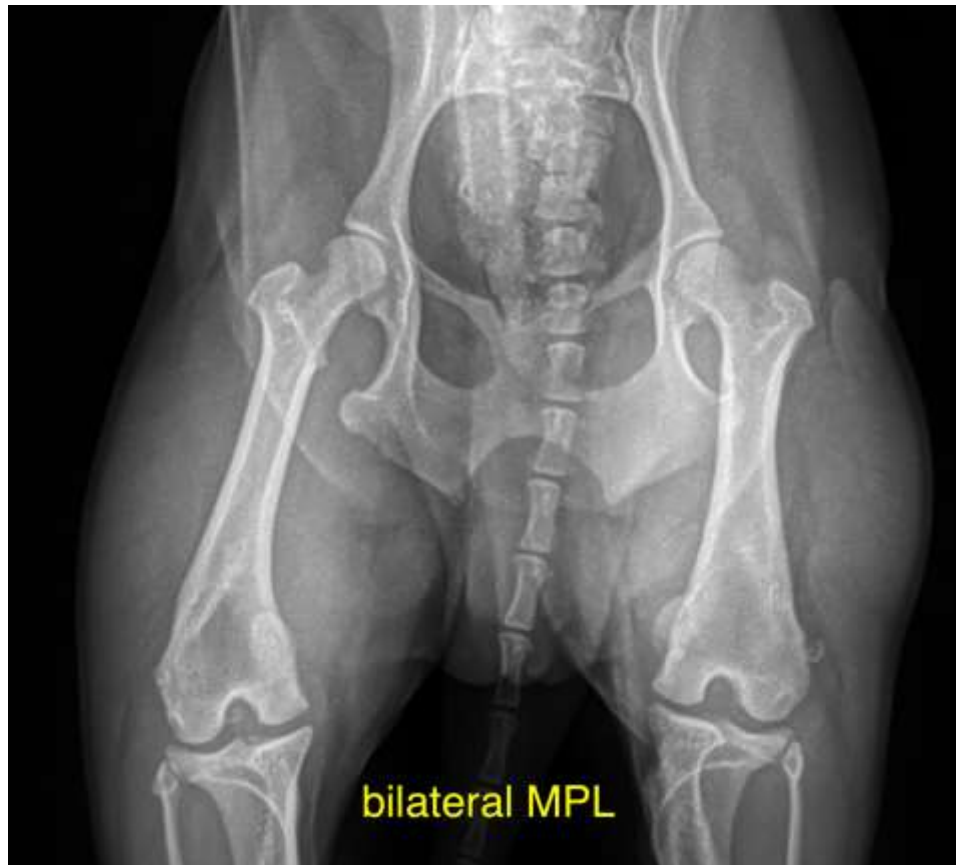
MN

AGE

5

INTERPRETED BY

Nele Eley, DVM
Dr. med. Vet. DipECVDI



HOSPITAL NAME

Rockaway Animal
Hospital

REFERRING VET

Dr. Maniar

INVOICE

47025

DATE

8-18-21

The information and recommendations provided are based on the images presented by the referring veterinarian. No evaluation can be communicated regarding pathology that was not visible in the image/video clips provided.

Thank you for this referral. If the clinical or image interpretation does not parallel your findings or if I can be of any further assistance please contact me.

Nele Eley, DVM, Dr. med. vet., DipECVDI
European Specialist in Veterinary Diagnostic Imaging, Cert. Radiology,
Senior lecturer University of Giessen, Germany, Veterinary Faculty, Department of Radiology
Nele.Eley@sonopath.com