



PATIENT

Max Foster

PRESENTING CLINICAL SIGNS

Hacking cough since 3 days. Started Clavamox drops & Hydrocodone yesterday. The cough is getting worse since then. Eating improved today. Nasal discharge, getting better since yesterday. Up to date vaccine including Bordetella.

SPECIES

Canine

Abnormal PE/Chem/CBC/UA Results: Severe cough & clear nasal discharge. No fever. Could not recognize wheezes or crackles sounds.

RADIOGRAPHIC STUDY OF THE THORAX

BREED

Shih Tzu

Right/left lateral and ventrodorsal views totaling 4 images available for review.

RADIOGRAPHIC FINDINGS

SEX

Male

Moderate tracheal collapse is seen consistently throughout all lateral views level with the thoracic inlet. No evidence of concurrent bronchial collapse is noted.

The radiographic presentation of the cardiac silhouette is considered within normal limits.

The degree of pulmonary inflation is deep. A mild generalized bronchointerstitial lung pattern is noted with even distribution throughout the lung.

AGE

20 Weeks

There is moderate gastric aerophagia in a post-prandial stomach.

The size of the liver is considered within normal limits in relation to the patient's age.

INTERPRETED BY

Nele Eley, DVM
Dr. med. Vet. DipECVDF

RADIOGRAPHIC DIAGNOSIS

- Moderate caudocervical tracheal collapse.
- Mild generalized bronchointerstitial lung pattern.
- Normal radiographic presentation of the cardiac silhouette.

HOSPITAL NAME

Creditview-Eglinton
Animal Hospital

INTERPRETATION OF THE FINDINGS & FURTHER RECOMMENDATIONS

The radiographic study reveals moderate caudocervical tracheal collapse which appears to be present consistently throughout all lateral views provided. Degenerative bronchomalacia is unlikely in this very young patient and congenital collapse should be considered. Concurrent upper airway pathology cannot be ruled out. Consider further endoscopic evaluation to obtain a detailed assessment of the tracheal dynamics and to determine as to whether this patient renders suitable for tracheal stenting. Lower airway sampling could be considered at the same time in order to rule out presence of concurrent lower airway infection or inflammation as to the presence of a mild bronchointerstitial lung pattern.

REFERRING VET

Elhamy Ghobrial

INVOICE

47033

DATE

8-18-21



PATIENT

Max Foster

SPECIES

Canine

BREED

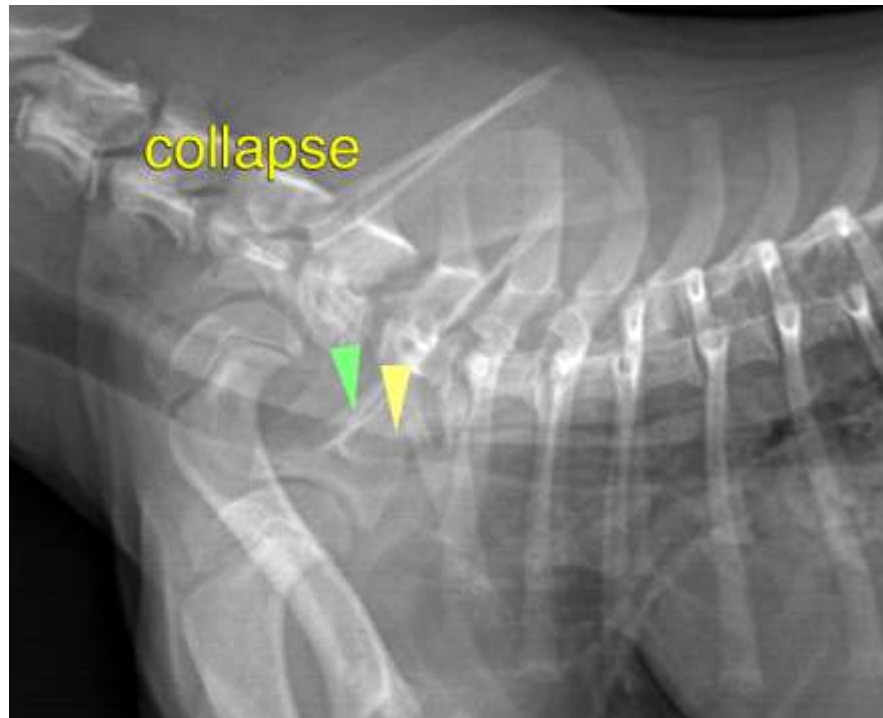
Shih Tzu

SEX

Male

AGE

20 Weeks



INTERPRETED BY

Nele Eley, DVM
Dr. med. Vet. DipECVDI

The information and recommendations provided are based on the images presented by the referring veterinarian. No evaluation can be communicated regarding pathology that was not visible in the image/video clips provided.

HOSPITAL NAME

Creditview-Eglinton
Animal Hospital

Thank you for this referral. If the clinical or image interpretation does not parallel your findings or if I can be of any further assistance please contact me.

REFERRING VET

Elhamy Ghobrial

Nele Eley, DVM, Dr. med. vet., DipECVDI
European Specialist in Veterinary Diagnostic Imaging, Cert. Radiology,
Senior lecturer University of Giessen, Germany, Veterinary Faculty, Department of Radiology
Nele.Eley@sonopath.com

INVOICE

47033

DATE

8-18-21