

**PATIENT**

Macie McGowan

PRESENTING CLINICAL SIGNS

Acute NWB LH lame. Severely painful with crepitus on palpation of L stifle.

SPECIES

Canine

RADIOGRAPHIC STUDY OF THE STIFLES

Mediolateral and craniocaudal views of both stifles available for review.

BREED

Mini Goldendoodle

Moderate articular swelling of the left stifle joint is seen.

SEX

FS

Two rounded bony structures of 3.5mm and 2.5mm, respectively, are isolated from the cranial and proximal aspect of the tibial plateau with a large but well delineated radiolucent halo in the proximal tibia.

A small cartilage remnant at the distal margin of the tibial tuberosity is seen in both stifles.

AGE

1 Year

The radiographic presentation of the right stifle is within normal limits otherwise.

Marked atrophy of the right hind limb musculature is seen on the orthogonal view.

INTERPRETED BYNele Eley, DVM
Dr. med. Vet. DipECVDI**RADIOGRAPHIC DIAGNOSIS**

- Left stifle arthropathy with isolated bone structures in the cranial margin of the tibial joint surface.
- Severe disuse atrophy of the right hind limb musculature.

INTERPRETATION OF THE FINDINGS & FURTHER RECOMMENDATIONS

Disturbed endochondral ossification such as osteochondritis dissecans is thought to be the most likely underlying cause of the pertinent radiographic changes with a main differential diagnosis of chronic avulsion fracture with rounded bone fragments of the distal insertion of the cranial cruciate ligament. Fragmentation of the tibia secondary to cranial cruciate ligament avulsion is uncommon. It is more common that the proximal insertion of the cranial cruciate ligament presents avulsion. In any case, involvement of the cranial cruciate ligament has to be considered and correlation with the clinical palpation for presence of increased laxity is required.

Arthroscopic revision eventually preceded by an MRI study could be considered in this patient's left stifle.

HOSPITAL NAMEBergen County
Veterinary Center**REFERRING VET**

Dr. Moore

INVOICE

47028

DATE

8-18-21



PATIENT

Macie McGowan

SPECIES

Canine

BREED

Mini Goldendoodle

SEX

FS

AGE

1 Year

INTERPRETED BY

Nele Eley, DVM
Dr. med. Vet. DipECVDI

HOSPITAL NAME

Bergen County
Veterinary Center

REFERRING VET

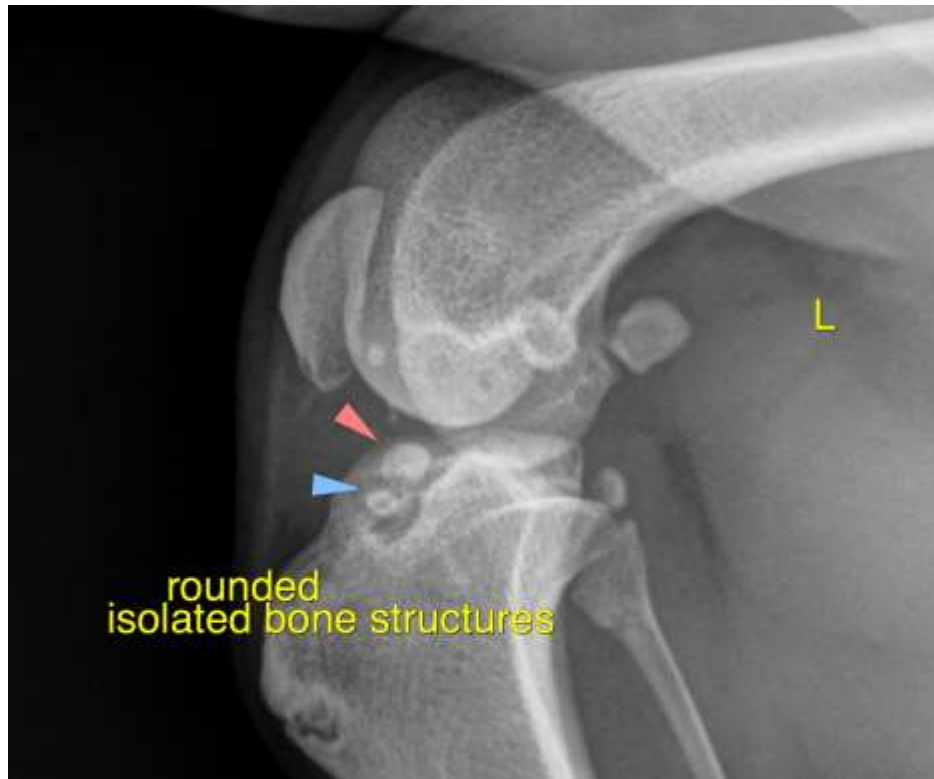
Dr. Moore

INVOICE

47028

DATE

8-18-21



The information and recommendations provided are based on the images presented by the referring veterinarian. No evaluation can be communicated regarding pathology that was not visible in the image/video clips provided.

Thank you for this referral. If the clinical or image interpretation does not parallel your findings or if I can be of any further assistance please contact me.

Nele Eley, DVM, Dr. med. vet., DipECVDI
European Specialist in Veterinary Diagnostic Imaging, Cert. Radiology,
Senior lecturer University of Giessen, Germany, Veterinary Faculty, Department of Radiology
Nele.Eley@sonopath.com