

**PATIENT**

Emmy Kazmierski

PRESENTING CLINICAL SIGNS

Trouble breathing, febrile. 104.8. Decreased appetite and lethargy after cortisone injection.
Abnormal PE/Chem/CBC/UA Results: Rad Thoracic air Broncho grams?

SPECIES

Feline

RADIOGRAPHIC STUDY OF THE THORAX

Single left lateral view of the thorax and abdomen available for review.

Thoracic read requested.

BREED

DSH

RADIOGRAPHIC FINDINGS

The degree of pulmonary inflation is moderate. A lobar alveolar sign of the right middle lobe with air bronchograms is seen and superimposed onto the cardiac silhouette. A moderate generalized bronchial lung pattern with caudodorsal accentuation is seen. There appears to be plate-like atelectasis of the lung in the caudodorsal lung field caudal of the heart base. However, a second infiltrate in this position cannot be ruled out entirely.

SEX

FS

Prominence of the caudal vena cava is noted.

AGE

17 Years

Mild esophageal aerophagia is noted.

RADIOGRAPHIC DIAGNOSIS**INTERPRETED BY**

Nele Eley, DVM
Dr. med. Vet. DipECVDI

- Lobar alveolar sign of the right middle lobe.
- Bronchial lung pattern with presumed plate-like atelectasis.

INTERPRETATION OF THE FINDINGS & FURTHER RECOMMENDATIONS

The radiographic study of the thorax reveals a lobar alveolar sign of the right middle lobe with a generalized bronchial lung pattern. Differential diagnosis includes atelectasis due to mucus plugging with chronic allergic lower airway syndrome; however, lobar pneumonia and less likely lobar neoplasia cannot be ruled out entirely as differential diagnoses. It is hard to tell whether the lobar sign of the right middle lobe represents an actual infiltrate or uncomplicated atelectasis, which is thought more likely, however, cannot be ascertained without either an orthogonal view or further testing such as ultrasound guided fine needle aspiration or airway sampling. A clinical trial of treatment for feline asthma and lobar pneumonia could be considered along with recheck radiographs alternatively.

HOSPITAL NAME

Hamburg Veterinary
Clinic

REFERRING VET

Dr. Shaw

INVOICE

47020

DATE

8-18-21



PATIENT

Emmy Kazmierski

SPECIES

Feline

BREED

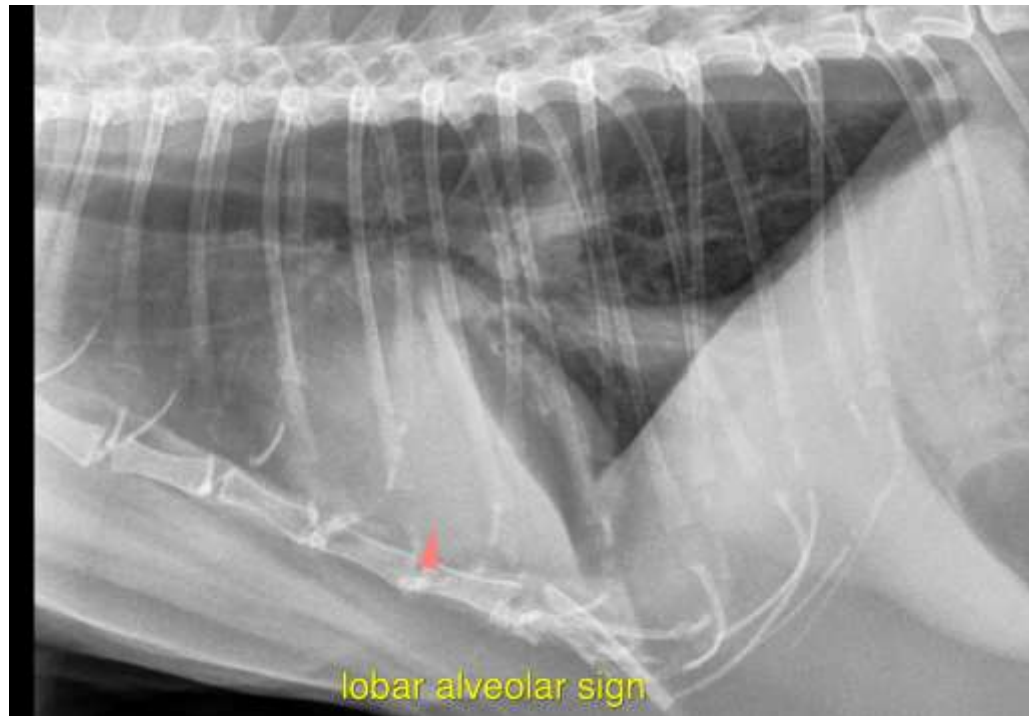
DSH

SEX

FS

AGE

17 Years



INTERPRETED BY

Nele Eley, DVM
Dr. med. Vet. DipECVDI

The information and recommendations provided are based on the images presented by the referring veterinarian. No evaluation can be communicated regarding pathology that was not visible in the image/video clips provided.

HOSPITAL NAME

Hamburg Veterinary
Clinic

Thank you for this referral. If the clinical or image interpretation does not parallel your findings or if I can be of any further assistance please contact me.

Nele Eley, DVM, Dr. med. vet., DipECVDI
European Specialist in Veterinary Diagnostic Imaging, Cert. Radiology,
Senior lecturer University of Giessen, Germany, Veterinary Faculty, Department of Radiology
Nele.Eley@sonopath.com

REFERRING VET

Dr. Shaw

INVOICE

47020

DATE

8-18-21