



PATIENT

Boris Burgstahler

PRESENTING CLINICAL SIGNS

Regurgitates 10 minutes after eating. R/O mega esophagus. Diabetic
Abnormal PE/Chem/CBC/UA Results: Blood pending

SPECIES

Canine

RADIOGRAPHIC STUDY OF THE THORAX

Single left lateral view available for review.

BREED

Poodle Mix

RADIOGRAPHIC FINDINGS

Course and width of the trachea are considered within normal limits.

No abnormal dilation of the esophagus is seen.

SEX

MN

The cardiac silhouette presents within normal limits. The vertebral heart score is 9.6. There is no evidence of specific chamber enlargement. The pulmonary vasculature presents within normal limits.

AGE

12 Years

A mild generalized bronchointerstitial lung pattern is seen with multiple pulmonary osteomas which is considered within age related normal limits.

No evidence of mediastinal lymphadenomegaly is noted.

There appears to be moderate generalized enlargement of the liver with rounded lobar margins.

A mild amount of gravel is seen in the gastric pylorus.

A fat opaque subcutaneous structure ventral of the mid abdominal wall is seen and suggestive for lipoma versus small umbilical hernia.

INTERPRETED BY

Nele Eley, DVM
Dr. med. Vet. DipECVDI

HOSPITAL NAME

Hamburg Veterinary
Clinic

RADIOGRAPHIC DIAGNOSIS

- Normal age related thorax.
- No radiographic evidence of megaesophagus.
- Moderate generalized hepatomegaly.

REFERRING VET

Dr. Branning

INTERPRETATION OF THE FINDINGS & FURTHER RECOMMENDATIONS

The radiographic study is negative for esophageal dilation. Consider swallowing disorder or esophageal dysphagia a potential. A barium swallow with fluoroscopy would be ideal to obtain more information about the esophageal function.

INVOICE

47032

Differential diagnosis for the hepatomegaly includes metabolic/endocrine hepatopathy. Diffuse neoplastic or inflammatory infiltrates cannot be ruled out. Correlate with the laboratory values and consider ultrasound with eventual parenchymal sampling if indicated.

DATE

8-18-21



PATIENT

Boris Burgstahler

SPECIES

Canine

BREED

Poodle Mix

SEX

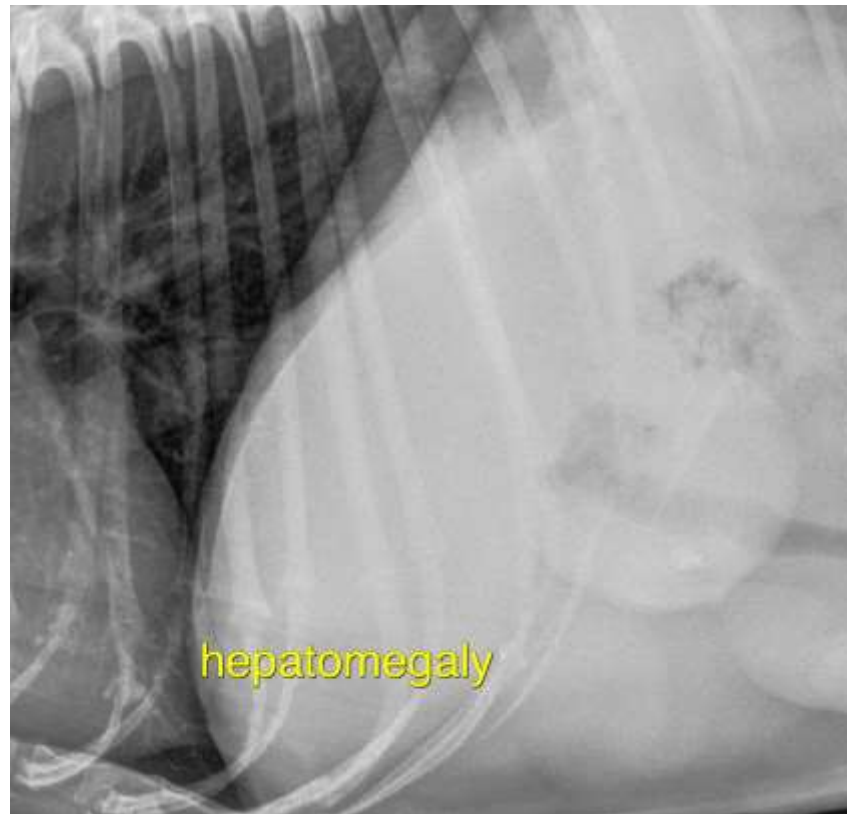
MN

AGE

12 Years

INTERPRETED BY

Nele Eley, DVM
Dr. med. Vet. DipECVDI



HOSPITAL NAME

Hamburg Veterinary
Clinic

REFERRING VET

Dr. Branning

INVOICE

47032

DATE

8-18-21

The information and recommendations provided are based on the images presented by the referring veterinarian. No evaluation can be communicated regarding pathology that was not visible in the image/video clips provided.

Thank you for this referral. If the clinical or image interpretation does not parallel your findings or if I can be of any further assistance please contact me.

Nele Eley, DVM, Dr. med. vet., DipECVDI
European Specialist in Veterinary Diagnostic Imaging, Cert. Radiology,
Senior lecturer University of Giessen, Germany, Veterinary Faculty, Department of Radiology
Nele.Eley@sonopath.com