

**PATIENT**

Holly Lucas

PRESENTING CLINICAL SIGNS

rDVM removed a small growth from anterior aspect of LF paw in Spring 2023 but not sent for histo. Growth had been present for 2 years. Since surgery, has been licking at food. Abnormal PE/Chem/CBC/UA Results: Mild restriction to extension of 4th digit, 1st IPJ but normal radiographs of digits. Swelling noted to proximal aspect of metacarpal pad compared to RF foot. FNA taken and increased numbers of neutrophils noted.

SPECIES

Canine

ULTRASONOGRAPHIC FINDINGS**BREED**

Beagle X

Left Palmar Metacarpus

The ultrasonographic study reveals a lined fluid accumulation palmar and distal to the 4th digit's metacarpophalangeal joint. A regular hypoechoic wall of 1.0-1.5mm thickness is seen circumferential to a slightly branching accumulation of anechoic fluid. Mild peripheral soft tissue swelling with fat stranding is noted. The lined fluid accumulation appears to connect to the palmar aspect of the metacarpophalangeal joint. No osseous changes are seen.

SEX

FS

ULTRASONOGRAPHIC DIAGNOSIS

- Suspect synovial hernia of the 4th digit's metacarpophalangeal joint in the left front limb.

AGE

11 Years

INTERPRETATION OF THE FINDINGS & FURTHER RECOMMENDATIONS

The ultrasonographic study reveals a lined fluid accumulation in the palmar aspect of the 4th digit's metacarpophalangeal joint which appears to connect to the articular space. Synovial hernia is a primary differential diagnosis and underlying arthropathy such as inflammatory including immune mediated, post-traumatic, and by far less likely infectious are potential underlying causes. Correlation with the results of the sampling recommended.

INTERPRETED BY

Nele Eley, DVM
Dr. med. Vet. DipECVDI

HOSPITAL NAME

Cedarview Animal
Hospital

REFERRING VET

Nigel Gumley

INVOICE

59799

DATE

8-17-23



PATIENT

Holly Lucas

SPECIES

Canine

BREED

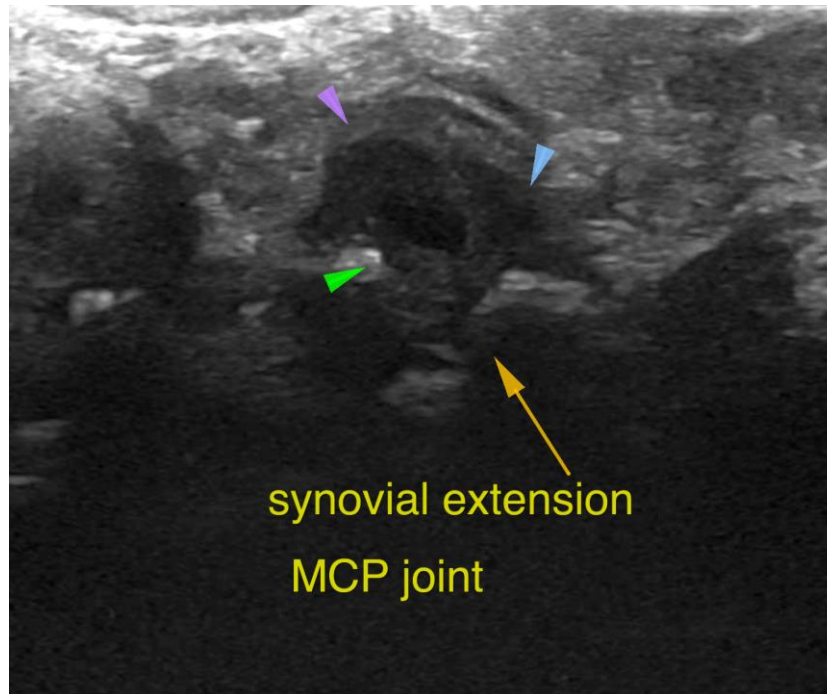
Beagle X

SEX

FS

AGE

11 Years



INTERPRETED BY

Nele Eley, DVM
Dr. med. Vet. DipECVDI

The information and recommendations provided are based on the images presented by the referring veterinarian/sonographer. No evaluation can be communicated regarding pathology that was not visible in the image/video clips provided.

Thank you for this referral. If the clinical or image interpretation does not parallel your findings or if I can be of any further assistance please contact me.

HOSPITAL NAME

Cedarview Animal
Hospital

Nele Eley, DVM, Dr. med. vet., DipECVDI
European Specialist in Veterinary Diagnostic Imaging, Cert. Radiology,
Senior lecturer University of Giessen, Germany, Veterinary Faculty, Department of Radiology
info@sonopath.com

REFERRING VET

Nigel Gumley

INVOICE

59799

DATE

8-17-23