



PATIENT

Zoe Pozdnik

PRESENTING CLINICAL SIGNS

History of favoring the left knee for months. Has bilateral joint effusion but is just favoring the left knee at this time. TTA Left knee

SPECIES

Canine

Abnormal PE/Chem/CBC/UA Results: Positive CR Drawer, Positive CTT, Medial buttress, Increased Joint effusion, discolored synovium, Torn CCL with a small incompetent band still present, Severe damage to the medial meniscus torn caudally and folded forward. Osteophytes moderate

BREED

Akita Mix

ULTRASONOGRAPHIC FINDINGS

Left Stifle

A moderate amount of anechoic effusion is seen within the supra- and infra- patellar recesses of the left stifle joint. There is moderate thickening of the synovial and capsular layers of the stifle. A moderate amount of periarticular osteophytes is seen.

SEX

FS

The cranial cruciate ligament presents as a stump of echogenic fibers at the intercondylar eminence of tibia with a halo of hypochoic effusion.

AGE

5 Years

The medial meniscus presents mild prolapse. A hypochoic vertical line is seen as well as a defect and a short transverse hypochoic line within the meniscal tissue within its mid and caudal portions.

ULTRASONOGRAPHIC DIAGNOSIS

- Cranial cruciate ligament rupture and medial meniscal injury as well as moderate chronic osteoarthritis of the left stifle.

INTERPRETED BY

Nele Eley, DVM
Dr. med. Vet. DipECVDI

INTERPRETATION OF THE FINDINGS & FURTHER RECOMMENDATIONS

The ultrasonographic findings are compatible with complete rupture of the left cranial cruciate ligament and suggest presence of concurrent meniscal injury with torn and prolapsing meniscal tissue.

HOSPITAL NAME

Westview Veterinary
Hospital

REFERRING VET

Dr Brian Barnes

INVOICE

53532

DATE

8-17-22



PATIENT

Zoe Pozdrik

SPECIES

Canine

BREED

Akita Mix

SEX

FS

AGE

5 Years

INTERPRETED BY

Nele Eley, DVM
Dr. med. Vet. DipECVDI

HOSPITAL NAME

Westview Veterinary
Hospital

REFERRING VET

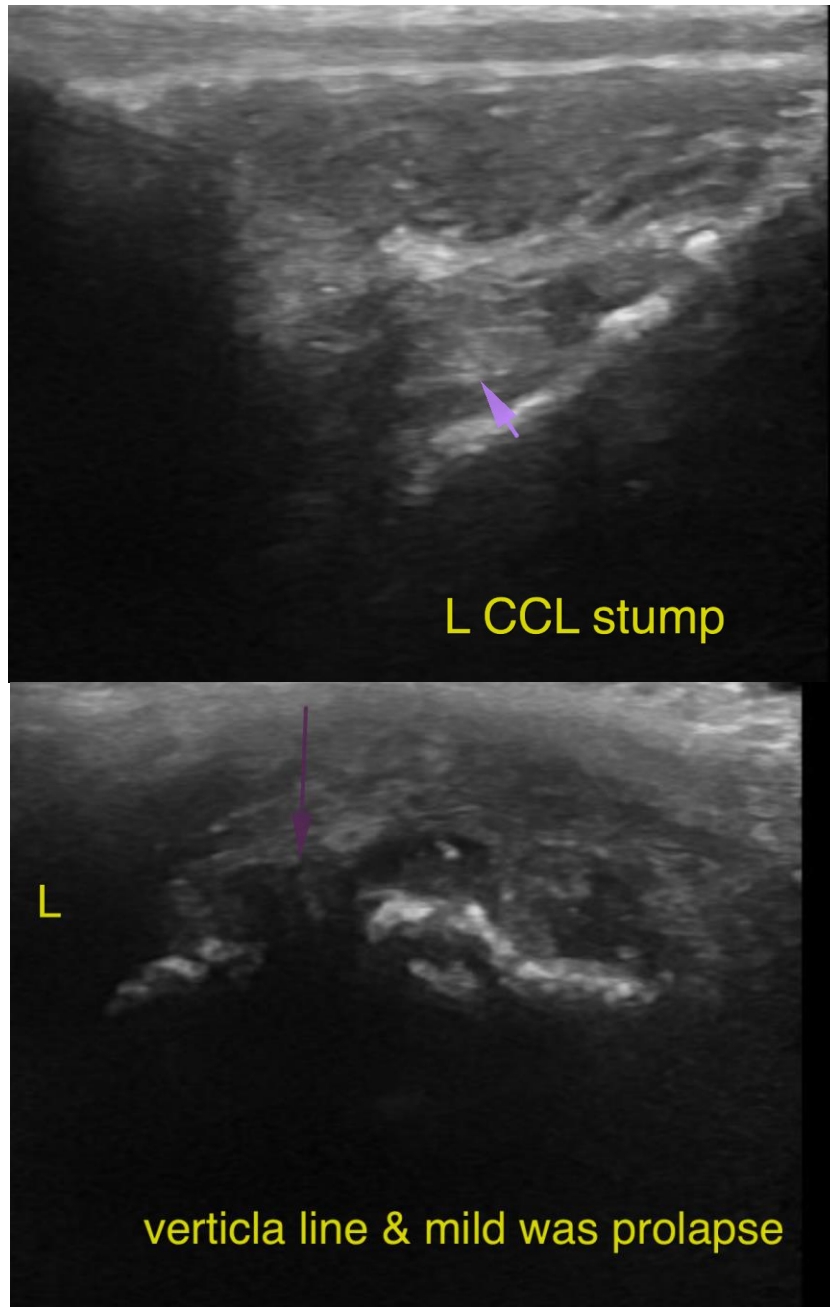
Dr Brian Barnes

INVOICE

53532

DATE

8-17-22





PATIENT

Zoe Pozdrik

SPECIES

Canine

BREED

Akita Mix

SEX

FS

AGE

5 Years

INTERPRETED BY

Nele Eley, DVM
Dr. med. Vet. DipECVDI

HOSPITAL NAME

Westview Veterinary
Hospital

REFERRING VET

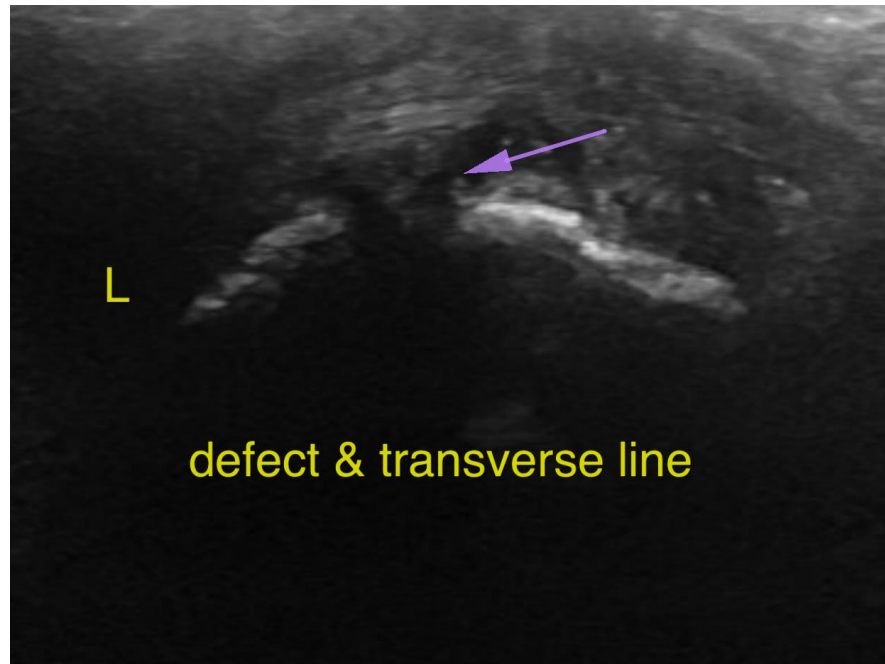
Dr Brian Barnes

INVOICE

53532

DATE

8-17-22



The information and recommendations provided are based on the images presented by the referring veterinarian/sonographer. No evaluation can be communicated regarding pathology that was not visible in the image/video clips provided.

Thank you for this referral. If the clinical or image interpretation does not parallel your findings or if I can be of any further assistance please contact me.

Nele Eley, DVM, Dr. med. vet., DipECVDI
European Specialist in Veterinary Diagnostic Imaging, Cert. Radiology,
Senior lecturer University of Giessen, Germany, Veterinary Faculty, Department of Radiology
Nele.Eley@sonopath.com