



**PATIENT PRESENTING CLINICAL SIGNS**

Willie G Friske Willie G presented to us about 1 month ago with history of sudden acute LH lameness. On PE, he was reactive to palpation of his left hind foot/tarsal region, and on flexion of his foot. There were no wounds or swellings or other PE abnormalities detected on orthopedic exam that day.

**SPECIES** Radiographs looked at by us at that time, were unremarkable to us (no fractures or bony lesions visible, other than mild osteoarthritic changes in both coxofemoral joints, and possible osteophyte on wing of ilium left side (positional?). The radiographs we took 1 month ago is what we have sent for interpretation today. He presented today for a recheck. He improved on NSAID (meloxicam) for the 7 days he was initially on them, and then about 3 days after discontinuing he became lame again. He will not put weight on the leg most of the time (sometimes toe-touching lame), but he will still jump onto the counter and stretch his legs out for grooming/etc. On PE today - Mild pain response on palpation of pelvis, no longer painful on palpation of his left hind, and mild pain response on palpation of stifle. Cost is a concern for this owner, so we did not repeat rads today, but are sending what we were able to take last time.

**BREED** DSH

**SEX** Abnormal PE/Chem/CBC/UA Results: No bloodwork performed. PE findings as above.

Feline

DSH

MN

MN

MN

**AGE**

12 Years

**INTERPRETED BY**

Nele Eley, DVM  
Dr. med. Vet. DipECVDI

**RADIOGRAPHIC STUDY OF THE LEFT TARSUS & PELVIS**

Ventrodorsal hip extended view of the pelvis and mediolateral flexed and neutral and dorsoplantar views of the left tarsus totaling 4 images available for review.

**RADIOGRAPHIC FINDINGS**

The coxofemoral joints present within age related normal limits. Minor osseous remodeling of the left acetabulum is seen.

There is a spike shaped osseous enthesophyte at the right iliac wing most likely in the position of the sartorius muscle origin.

The left hind limb presents moderate generalized muscle atrophy.

**HOSPITAL NAME**

Woodridge  
Veterinary Clinic

The tarsal, metatarsophalangeal, and phalangeal joints of the left hind limb present within normal limits.

**RADIOGRAPHIC DIAGNOSIS**

**REFERRING VET**

Anique McCrea-  
Spence

- Muscle atrophy in the left hind limb.
- Enthesophyte of the right sartorius muscle – likely clinically insignificant; differential diagnoses: osteochondroma/cartilaginous exostosis.

**INTERPRETATION OF THE FINDINGS & FURTHER RECOMMENDATIONS**

**INVOICE**

53546

Atrophy of the left hind limb musculature is noted with no obvious underlying cause being identified in the radiographic study of the pelvis and left tarsus. Consider atrophy secondary to disuse as well as neurogenic muscle atrophy. Full neurologic workup is recommended. Neurologic disease in particular involving the lumbar spine, cauda equina/left sciatic nerve, as well as soft tissue inflammation or injury appear to be potential causes of the patient’s clinical signs based on the radiographic changes.

**DATE**

8-17-22



**PATIENT**

Willie G Friske

**SPECIES**

Feline

**BREED**

DSH

**SEX**

MN

**AGE**

12 Years

**INTERPRETED BY**

Nele Eley, DVM  
Dr. med. Vet. DipECVDI

**HOSPITAL NAME**

Woodridge  
Veterinary Clinic

**REFERRING VET**

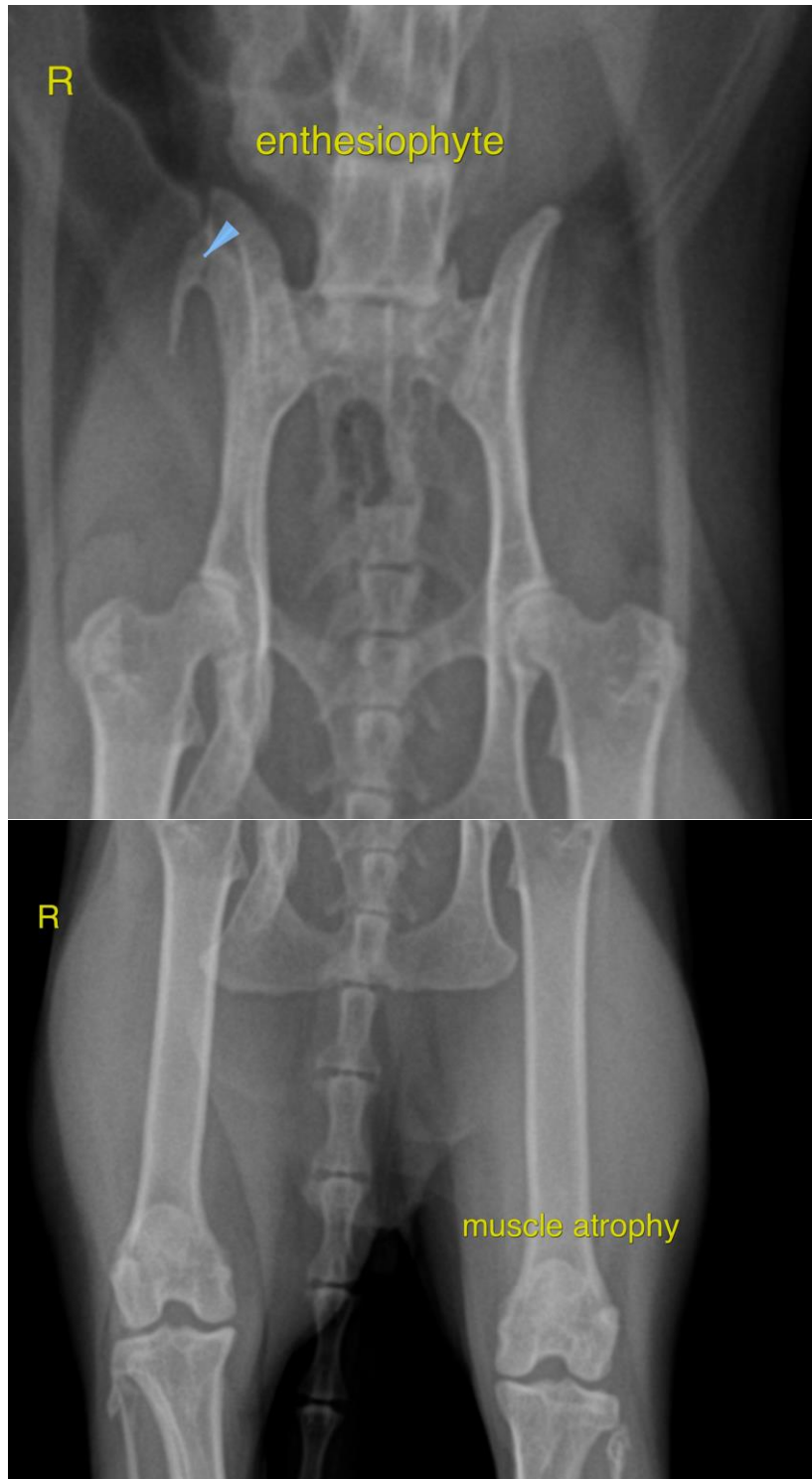
Anique McCrea-  
Spence

**INVOICE**

53546

**DATE**

8-17-22





**PATIENT**

Willie G Friske

The information and recommendations provided are based on the images presented by the referring veterinarian/sonographer. No evaluation can be communicated regarding pathology that was not visible in the image/video clips provided.

**SPECIES**

Feline

Thank you for this referral. If the clinical or image interpretation does not parallel your findings or if I can be of any further assistance please contact me.

**BREED**

DSH

**Nele Eley**, DVM, Dr. med. vet., DipECVDI  
European Specialist in Veterinary Diagnostic Imaging, Cert. Radiology,  
Senior lecturer University of Giessen, Germany, Veterinary Faculty, Department of Radiology  
Nele.Eley@sonopath.com

**SEX**

MN

**AGE**

12 Years

**INTERPRETED BY**

Nele Eley, DVM  
Dr. med. Vet. DipECVDI

**HOSPITAL NAME**

Woodridge  
Veterinary Clinic

**REFERRING VET**

Anique McCrea-  
Spence

**INVOICE**

53546

**DATE**

8-17-22