

**PATIENT**

Joe Vargas

PRESENTING CLINICAL SIGNS

2 month history of difficulty getting up Exam: Bilateral knee flexion pain and Cr dr

SPECIES

Canine

ULTRASONOGRAPHIC FINDINGS**Right Stifle**

A mild amount of effusion is present within the supra- and infra- patellar recesses of the right stifle joint. There is swelling of the synovium as well as heterogeneity of the infrapatellar fat pad.

BREED

Cattle Dog

The cranial cruciate ligament presents as an echogenic stump at the intercondylar eminence of the tibia surrounded by an anechoic halo.

Cranial and mid portions of the medial meniscus are seen and present in situ and intact.

SEX

MN

Left Stifle

A mild amount of effusion is present within the supra- and infra- patellar recesses of the left stifle joint. There is swelling of the synovium as well as heterogeneity of the infrapatellar fat pad.

AGE

5 Years

The cranial cruciate ligament presents as an echogenic stump at the intercondylar eminence of the tibia surrounded by an anechoic halo.

Cranial and mid portions of the medial meniscus are seen and present in situ and intact.

INTERPRETED BY

Nele Eley, DVM
Dr. med. Vet. DipECVDI

ULTRASONOGRAPHIC DIAGNOSIS

- Bilateral stifle osteoarthritis with cranial cruciate ligament pathology.

INTERPRETATION OF THE FINDINGS & FURTHER RECOMMENDATIONS

The ultrasonographic findings support the presence of bilateral cranial cruciate ligament rupture. Moderate concurrent osteoarthritic changes are seen. A concurrent meniscal tear is not directly seen with the limitation that the caudal horns were not fully imaged. Biomechanical failure of the cranial cruciate ligament is assumed to be present in both stifles and may need to be addressed by surgical intervention.

HOSPITAL NAME

Colorado Animal
Specialty &
Emergency

REFERRING VET

Gaynor

INVOICE

53536

DATE

8-17-22



PATIENT

Joe Vargas

SPECIES

Canine

BREED

Cattle Dog

SEX

MN

AGE

5 Years

INTERPRETED BY

Nele Eley, DVM
Dr. med. Vet. DipECVDI

HOSPITAL NAME

Colorado Animal
Specialty &
Emergency

REFERRING VET

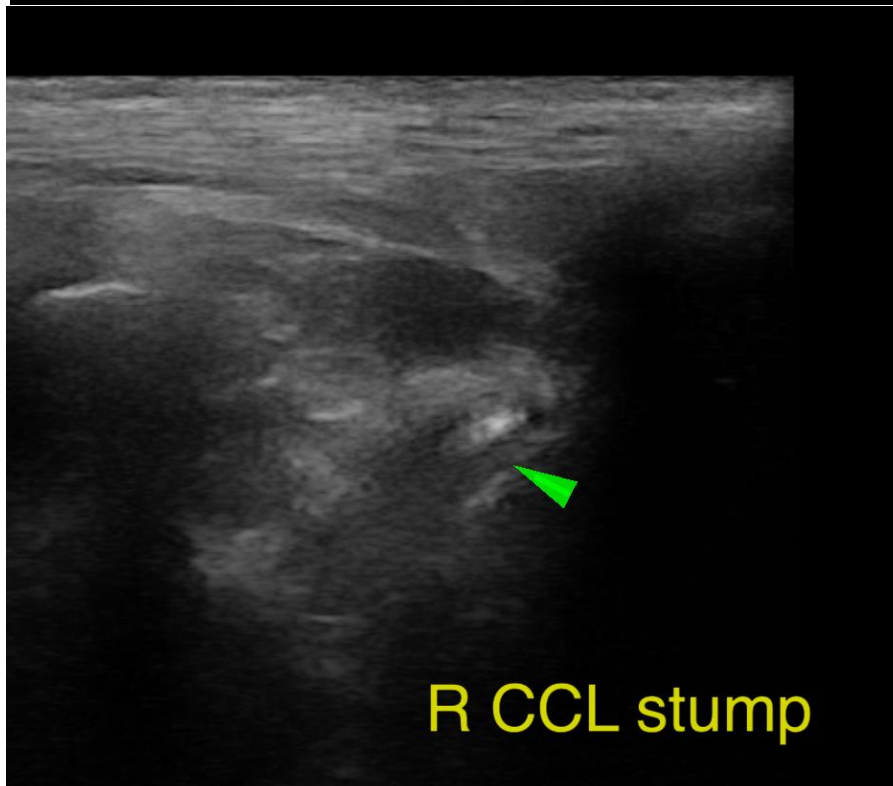
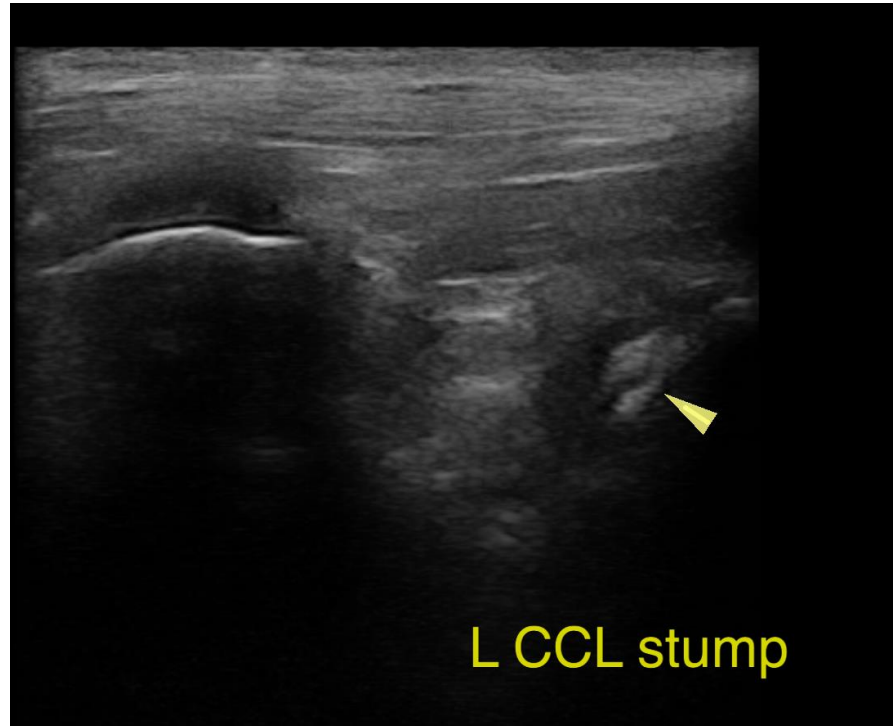
Gaynor

INVOICE

53536

DATE

8-17-22





PATIENT

Joe Vargas

The information and recommendations provided are based on the images presented by the referring veterinarian/sonographer. No evaluation can be communicated regarding pathology that was not visible in the image/video clips provided.

Thank you for this referral. If the clinical or image interpretation does not parallel your findings or if I can be of any further assistance please contact me.

SPECIES

Canine

Nele Eley, DVM, Dr. med. vet., DipECVDI
European Specialist in Veterinary Diagnostic Imaging, Cert. Radiology,
Senior lecturer University of Giessen, Germany, Veterinary Faculty, Department of Radiology
Nele.Eley@sonopath.com

BREED

Cattle Dog

SEX

MN

AGE

5 Years

INTERPRETED BY

Nele Eley, DVM
Dr. med. Vet. DipECVDI

HOSPITAL NAME

Colorado Animal
Specialty &
Emergency

REFERRING VET

Gaynor

INVOICE

53536

DATE

8-17-22