



PATIENT

Felix Iglesias

PRESENTING CLINICAL SIGNS

History of coughing, indoors only but was feral as a kitten/young cat. On P.E. wheezing noted on the 2 right quadrants, otherwise unremarkable finding.
Abnormal PE/Chem/CBC/UA Results: Blood work not performed

SPECIES

Feline

RADIOGRAPHIC STUDY OF THE THORAX & ABDOMEN

Right lateral and ventrodorsal whole body views totaling 2 images available for review.

BREED

Domestic Shorthair

RADIOGRAPHIC FINDINGS

Thorax

The patient is obese.

SEX

Male Neutered

Moderate ventrally bridging spondyloses are seen throughout the thoracic spine.

AGE

10 Years

The degree of pulmonary inflation is fair. No abnormal expansion of the ribcage is seen. A moderate generalized bronchial lung pattern is noted with even distribution throughout the lung. The opacity of the cranial lung lobes is mildly increased which, however, is only seen on the lateral view and not repeated on the orthogonal view and thought to be due to poor inflation.

Mild esophageal aerophagia is noted.

INTERPRETED BY

Nele Eley, DVM
Dr. med. Vet. DipECVDI

Course and width of the trachea are considered within normal limits.

The radiographic presentation of the cardiac silhouette is within normal limits.

Abdomen

HOSPITAL NAME

Paws and Claws
Urgent Care

Two diablo lead bullets are seen immediately adjacent and to the right of the 2nd lumbar vertebra. The bullets are fragmented and deformed. No evidence of associated osseous injury is seen.

Moderate spondyloses are present at L5/6 and L7/S1.

The serosal detail is maintained throughout the peritoneal and retroperitoneal space.

REFERRING VET

Dr. Juarez

The liver is appropriate in position, size and presents uniform opacity.

The splenic head is in the anticipated position and within normal limits for size and opacity. The splenic tail is not seen.

INVOICE

47009

Both kidneys are seen and present with normal size, shape, delineation and opacity. The urinary bladder is in its anticipated position. No radiopaque calculi are noted throughout the upper and lower urinary tract.

DATE

8-17-21

The stomach is in its anticipated position and presents normal content.

The small intestinal loops are of even diameter and non-dilated, a small amount of gas is seen within the small intestinal loops and considered within normal limits.



PATIENT

Felix Iglesias

The colon is seen in the expected position and presents with appropriate content.

RADIOGRAPHIC DIAGNOSIS

SPECIES

Feline

- Moderate bronchial lung pattern.
- Multiple spondyloses.
- Diablo bullets level with the 2nd lumbar vertebra - without evidence of osseous injury.
- Lumbosacral stenosis.
- Radiographically normal abdomen.

BREED

Domestic Shorthair

INTERPRETATION OF THE FINDINGS & FURTHER RECOMMENDATIONS

SEX

Male Neutered

A moderate generalized bronchial lung pattern is seen and may either be due to chronic allergic lower airway syndrome or infectious bronchitis such as viral, bacterial, parasitic, or protozoal. Airway sampling would be ideal for further definition. A clinical trial of treatment for bronchitis could be considered alternatively.

AGE

10 Years

The radiographic presentation of the abdomen is within normal limits. The spondyloses and presence of the diablo bullets are considered unrelated to the reason of clinical presentation and most likely to be incidental.

INTERPRETED BY

Nele Eley, DVM
Dr. med. Vet. DipECVDI

HOSPITAL NAME

Paws and Claws
Urgent Care

REFERRING VET

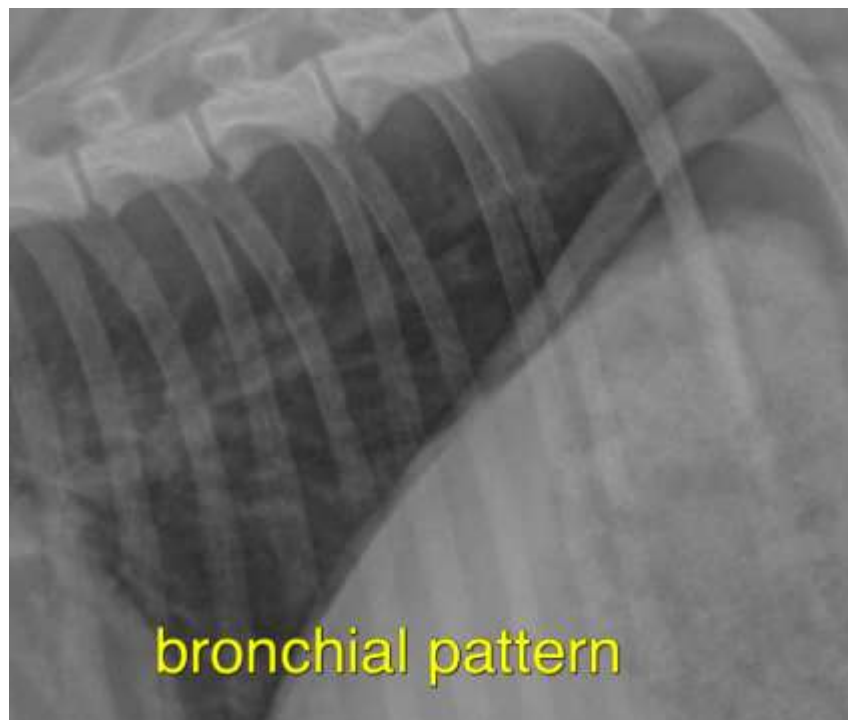
Dr. Juarez

INVOICE

47009

DATE

8-17-21





PATIENT

Felix Iglesias

The information and recommendations provided are based on the images presented by the referring veterinarian. No evaluation can be communicated regarding pathology that was not visible in the image/video clips provided.

SPECIES

Feline

Thank you for this referral. If the clinical or image interpretation does not parallel your findings or if I can be of any further assistance please contact me.

BREED

Domestic Shorthair

Nele Eley, DVM, Dr. med. vet., DipECVDI
European Specialist in Veterinary Diagnostic Imaging, Cert. Radiology,
Senior lecturer University of Giessen, Germany, Veterinary Faculty, Department of Radiology
Nele.Eley@sonopath.com

SEX

Male Neutered

AGE

10 Years

INTERPRETED BY

Nele Eley, DVM
Dr. med. Vet. DipECVDI

HOSPITAL NAME

Paws and Claws
Urgent Care

REFERRING VET

Dr. Juarez

INVOICE

47009

DATE

8-17-21