

**PATIENT**

Aster Timinski

PRESENTING CLINICAL SIGNS

Has been seen in weird spots in the house that she has never been before. Is more vocal than normal as well. Has lost a lot of weight since we saw her last. We are on Prozac and Methimazole. Did an Ultrasound August 4th.

SPECIES

Feline

Abnormal PE/Chem/CBC/UA Results: PE: SLIGHTLY DEHYDRATED, BROKEN UPPER CANINE TOOTH, MISSING TEETH, No masses. Shaved from ultrasound but healthy hair coat. No recent labs

BREED

DSH

RADIOGRAPHIC STUDY OF THE THORAX

Right/left lateral and ventrodorsal whole body views totaling 3 images available for review.

Thoracic read requested.

SEX

Spayed

RADIOGRAPHIC FINDINGS

A series of mild spondyloses are seen in the mid and caudal thoracic spine.

The radiographic presentation of the cardiac silhouette is within normal limits.

AGE

15 Years, 9 Months

Course and width of the trachea are considered within normal limits.

There is no evidence of mediastinal widening.

INTERPRETED BY

Nele Eley, DVM
Dr. med. Vet. DipECVDI

The degree of pulmonary inflation is moderate. A moderate generalized bronchial lung pattern is seen with even distribution throughout the lung.

Mild expansion of the ribcage is seen as well as mild widening of the lumbodiaphragmatic angle.

HOSPITAL NAME

Elizabeth Animal
Hospital

RADIOGRAPHIC DIAGNOSIS

- Moderate chronic lower airway pattern with early air trapping.
- Multiple age related and presumably incidental spondyloses.

REFERRING VET

Kim Allyn, DVM

INTERPRETATION OF THE FINDINGS & FURTHER RECOMMENDATIONS

The radiographic findings are suggestive for chronic allergic lower airway syndrome/feline asthma. Infectious bronchitis such as viral, bacterial, parasitic, or protozoal cannot be ruled out as a differential diagnosis entirely. The changes may not necessarily be of clinical significance at this point and further definition and/or treatment are only indicated in case of pertinent clinical signs.

INVOICE

47008

DATE

8-17-21



PATIENT

Aster Timinski

SPECIES

Feline

BREED

DSH

SEX

Spayed

AGE

15 Years, 9 Months

INTERPRETED BY

Nele Eley, DVM
Dr. med. Vet. DipECVDI

HOSPITAL NAME

Elizabeth Animal
Hospital

REFERRING VET

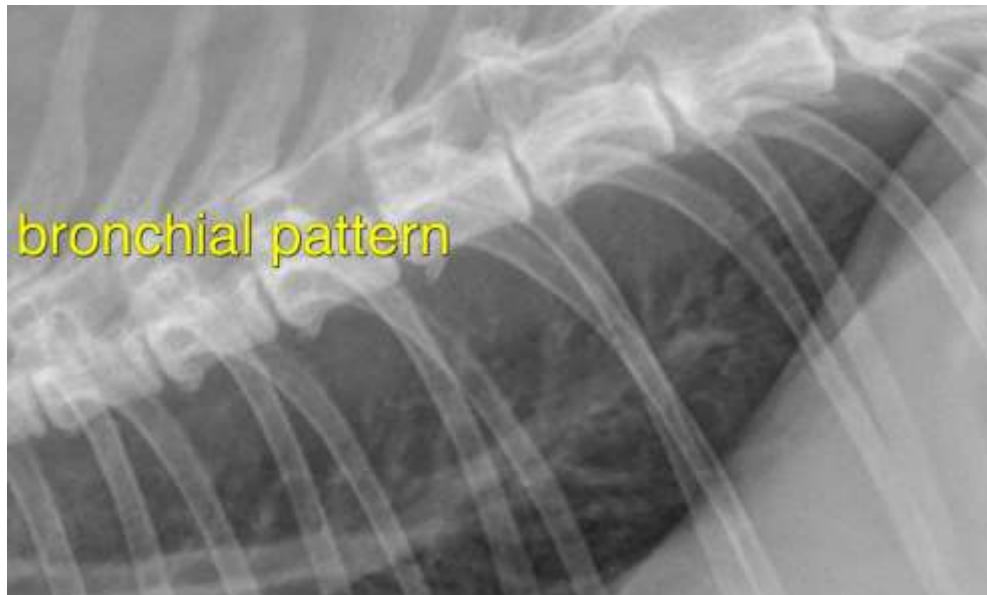
Kim Allyn, DVM

INVOICE

47008

DATE

8-17-21



The information and recommendations provided are based on the images presented by the referring veterinarian. No evaluation can be communicated regarding pathology that was not visible in the image/video clips provided.

Thank you for this referral. If the clinical or image interpretation does not parallel your findings or if I can be of any further assistance please contact me.

Nele Eley, DVM, Dr. med. vet., DipECVDI
European Specialist in Veterinary Diagnostic Imaging, Cert. Radiology,
Senior lecturer University of Giessen, Germany, Veterinary Faculty, Department of Radiology
Nele.Eley@sonopath.com