

**PATIENT**

Lola Huynh

PRESENTING CLINICAL SIGNS

Pt began having seizures 7/4/23, was started on Levetiracetam ER 500mg 1 tablet every 12 hours. Pt continued to have seizures, sometimes multiple in a day. Gabapentin was added to protocol, still is having cluster seizures

SPECIES

Canine

COMPUTED TOMOGRAPHIC STUDY OF THE HEAD

Plain and post contrast studies available for review.

BREEDPembroke Welsh
Corgi**COMPUTED TOMOGRAPHIC FINDINGS**

The CT study reveals an ovoid approximately 1 cm sized mass effect within the left temporal lobe of the brain. Mild diffuse increased contrast enhancement is noted within the mass effect. There is cerebral midline shift towards the right side. No evidence of ventricular dilation and no cerebellar herniation is seen.

SEX

FS

The regional lymph nodes present within normal limits.

Mild left frontal sinusitis is noted.

AGE

10 Years

The dentition is incomplete. Severe periodontal disease of the triadans 109, 209, and 409 is evident.

COMPUTED TOMOGRAPHIC DIAGNOSIS**INTERPRETED BY**Nele Eley, DVM
Dr. med. Vet. DipECVDI

- Intraaxial left temporal lobe mass effect of the brain.
- Left frontal sinusitis.
- Severe periodontal disease.

INTERPRETATION OF THE FINDINGS & FURTHER RECOMMENDATIONS

The CT study reveals a single intraaxial mass effect of the left cerebral hemisphere within the temporal lobe which appears to be perfused. Intraaxial neoplasia such as glial cell derived tumor is considered the most likely differential diagnosis. However, inflammatory/infectious pathology and cerebrovascular disease cannot be ruled out entirely as potential differential diagnoses even though being considered by far less likely. A more accurate differentiation of these pathologies may be possible with MRI.

HOSPITAL NAMEWilliamsport West
Veterinary Hospital**REFERRING VET**Stephanie Daverio,
VMD**INVOICE**

59759

DATE

8-16-23



PATIENT

Lola Huynh

SPECIES

Canine

BREED

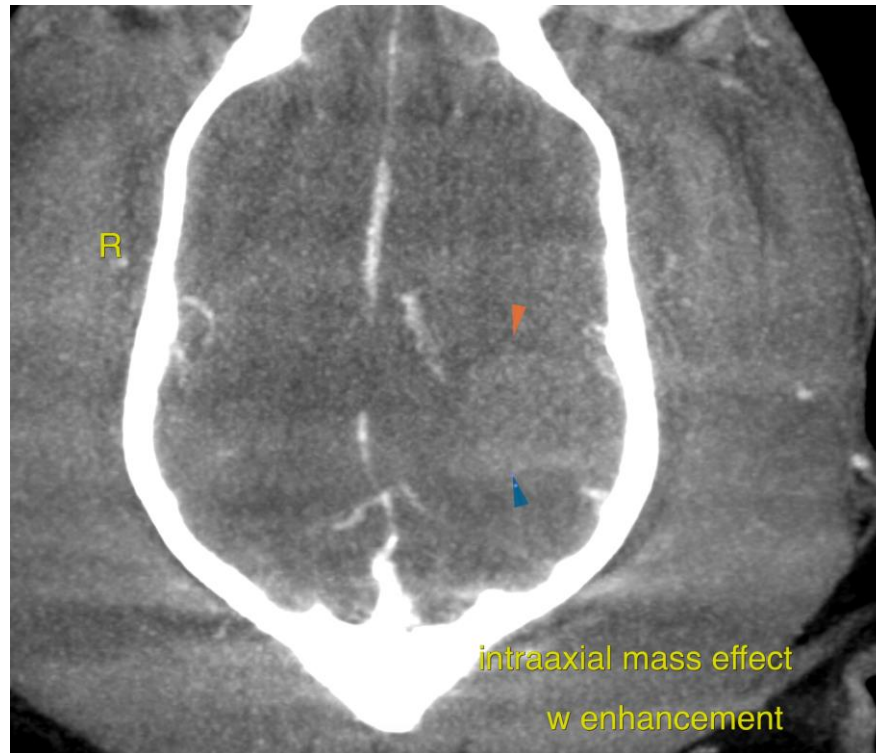
Pembroke Welsh
Corgi

SEX

FS

AGE

10 Years



INTERPRETED BY

Nele Eley, DVM
Dr. med. Vet. DipECVDI

The information and recommendations provided are based on the images presented by the referring veterinarian/sonographer. No evaluation can be communicated regarding pathology that was not visible in the image/video clips provided.

HOSPITAL NAME

Williamsport West
Veterinary Hospital

Thank you for this referral. If the clinical or image interpretation does not parallel your findings or if I can be of any further assistance please contact me.

Nele Eley, DVM, Dr. med. vet., DipECVDI
European Specialist in Veterinary Diagnostic Imaging, Cert. Radiology,
Senior lecturer University of Giessen, Germany, Veterinary Faculty, Department of Radiology
info@sonopath.com

REFERRING VET

Stephanie Daverio,
VMD

INVOICE

59759

DATE

8-16-23