



PATIENT

Grayson Cuskelly

PRESENTING CLINICAL SIGNS

P has FIV, O thinks P is getting near EOL, e/d- getting thin but seems to be eating V/D- none that O notices Sleeps a lot Very congested, seems to have issues breathing Meds- none Indoor/outdoor, doesn't go out much currently PE notes: General Appearance: QAR, depressed; BCS 4-5/9 CRT/MM: WNL Eyes: Corneas clear, pupils normal size, symmetrical, sclera white, no ocular discharge Ears: No exudate observed, no redness present Oral Cavity: severe gingivitis, stomatis and ulceration of the caudal aspect of the teeth, purulent necrotic discharge from the mouth Nasal Cavity: bilateral chronic nasal congestion and purulent discharge, worst in the right nostril; general nasal ulceration of the nasal planum Cardiovascular: Regular rhythm; no murmur detected Respiratory: Lungs auscultate clear bilaterally; trachea clear Abdomen: Abdomen palpates soft; no pain, tenderness or masses on palpation Rectal: Did not perform rectal exam Musculoskeletal: Normal ambulation/no lameness reported Integument: Normal amount of shedding; skin/coat WNL Lymph Nodes: Lymph nodes normal in size Urogenital: External genitalia appears normal Neurologic: No apparent abnormalities noted Assessment: chronic sinus congestion and discharge severe stomatitis and ulceration FIV positive, FeLV negative Given convenia and buprenorphine in the clinic
Abnormal PE/Chem/CBC/UA Results: TP 9.2 * g/dL, GLOB 6.7 * g/dL, NEU 14.15 10⁹/l, RBC 5.57 10¹²/l, HGB 7.0 g/dl, HCT 26.05 %, MCHC 26.7 g/dl

SPECIES

Feline

BREED

Domestic Shorthair

SEX

MN

AGE

12 Years, 2 Months

COMPUTED TOMOGRAPHIC STUDY OF THE HEAD

Plain study available for review.

INTERPRETED BY

Nele Eley, DVM
Dr. med. Vet. DipECVDI

COMPUTED TOMOGRAPHIC FINDINGS

Hyperostosis of the right frontal sinus is seen with mucosal swelling and fluid accumulation within the frontal sinus. Thinning of the right cribriform plate is noted.

There is extensive turbinate destruction within both nasal cavities with mucosal swelling and fluid accumulation accentuating the right nasal cavity.

HOSPITAL NAME

State Avenue Vet
Clinic

The left tympanic bulla is filled with fluid attenuating material. Slight expansion of the tympanic bulla and slight thinning of the skull base are noted. The external auditory meatuses present within normal limits. Minimal mucosal swelling is noted within the right tympanic bulla.

REFERRING VET

Dr. Jessie Evoniuk

The dentition is incomplete with multiple resorptive lesions.

COMPUTED TOMOGRAPHIC DIAGNOSIS

- Severe chronic bilateral destructive rhinosinusitis.
- Chronic left hand sided otitis media.
- Mild right hand sided otitis media.
- Incomplete dentition with multifocal FORL.

INVOICE

59768

INTERPRETATION OF THE FINDINGS & FURTHER RECOMMENDATIONS

DATE

8-16-23

The CT study reveals severe bilateral destructive rhinosinusitis. Chronic lymphoplasmacytic rhinitis is considered likely. Chronic infectious rhinitis such as viral, bacterial, mixed, or fungal cannot be ruled out entirely. There is no evidence of a soft tissue mass or foreign material. Further definition would require rhinoscopy with sampling if that has not been performed yet.



PATIENT

Grayson Cuskelly

The findings of the left tympanic bulla are compatible with chronic otitis media. Emerging tympanokeratoma formation cannot be ruled out. Mild right hand sided otitis media is noted as well.

SPECIES

Feline

BREED

Domestic Shorthair

SEX

MN

AGE

12 Years, 2 Months

INTERPRETED BY

Nele Eley, DVM
Dr. med. Vet. DipECVDI

HOSPITAL NAME

State Avenue Vet
Clinic

REFERRING VET

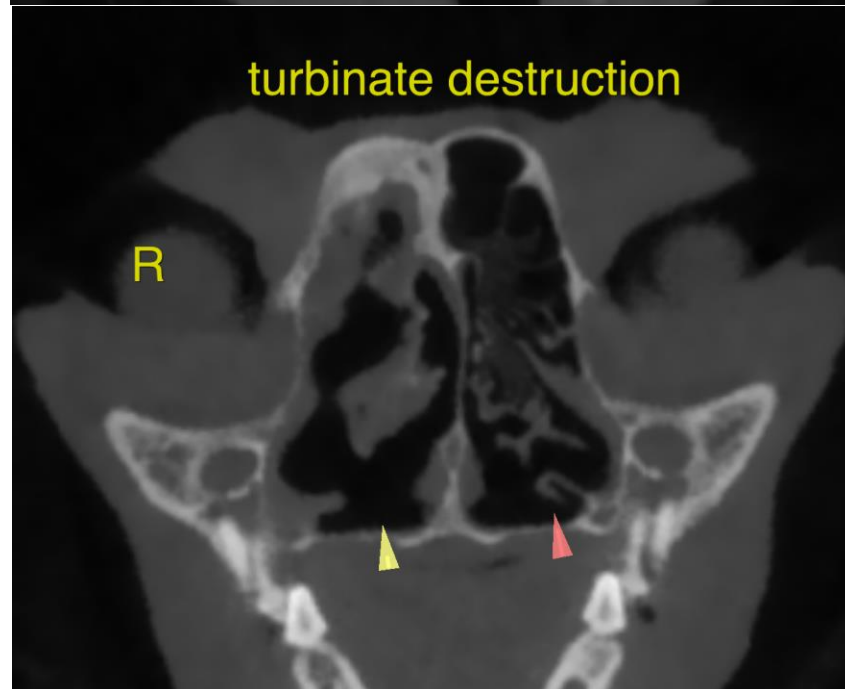
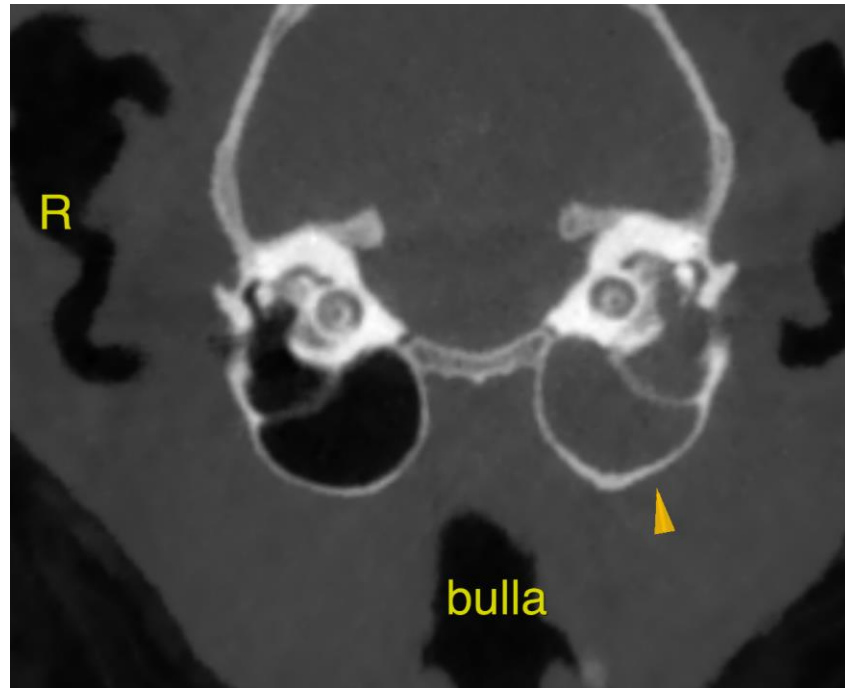Dr. Jessie Evoniuk

INVOICE

59768

DATE

8-16-23





PATIENT

Grayson Cuskelly

The information and recommendations provided are based on the images presented by the referring veterinarian/sonographer. No evaluation can be communicated regarding pathology that was not visible in the image/video clips provided.

SPECIES

Feline

Thank you for this referral. If the clinical or image interpretation does not parallel your findings or if I can be of any further assistance please contact me.

BREED

Domestic Shorthair

Nele Eley, DVM, Dr. med. vet., DipECVDI
European Specialist in Veterinary Diagnostic Imaging, Cert. Radiology,
Senior lecturer University of Giessen, Germany, Veterinary Faculty, Department of Radiology
info@sonopath.com

SEX

MN

AGE

12 Years, 2 Months

INTERPRETED BY

Nele Eley, DVM
Dr. med. Vet. DipECVDI

HOSPITAL NAME

State Avenue Vet
Clinic

REFERRING VET

Dr. Jessie Evoniuk

INVOICE

59768

DATE

8-16-23