



PATIENT PRESENTING CLINICAL SIGNS

Vader Hinson
 Unproductive cough that started around 7/22/22 . First Bordetella vaccine was given 7/14/22. Was at the groomer on 6/26, but otherwise not around unknown dogs. Coughing fits are more frequent; sneezing more than normal. no nasal discharge. Appetite down- 1/2 # weight loss in 3 weeks. Cough partially responsive to hydrocodone.

SPECIES
 Canine
 Abnormal PE/Chem/CBC/UA Results: BCS 7/9 Dry unproductive cough (hypersalivates when coughing) with increased lung sounds ventrally.

BREED
 Yorkie
RADIOGRAPHIC STUDY OF THE THORAX
 Right and left lateral and dorsoventral views of the thorax totaling 4 images available for review. One of the orthogonal views is right/left flipped.

SEX
 The patient is obese.

Male Neutered
 The radiographic presentation of the cardiac silhouette is within normal limits. The vertebral heart score is 9.4.

AGE
 11 Years
 Course and width of the trachea are considered within normal limits. There is no evidence of tracheal or bronchial collapse.

INTERPRETED BY
 The degree of pulmonary inflation is fair. A moderate bronchial lung pattern with mild multifocal cylindrical bronchiectasis is seen.

Nele Eley, DVM
 Dr. med. Vet. DipECVDI
 There appears to be mild generalized enlargement of the liver.
 Mild gastric aerophagia is noted.

HOSPITAL NAME RADIOGRAPHIC DIAGNOSIS

- Companion Animal Clinic
- Moderate generalized chronic bronchial lung pattern.
 - No radiographic evidence of cardiovascular pathology.
 - No radiographic evidence of dynamic tracheal disease.
 - Mild hepatomegaly.
 - Obesity.

REFERRING VET INTERPRETATION OF THE FINDINGS & FURTHER RECOMMENDATIONS

Varinia Acosta
 The radiographic study reveals a bronchial lung pattern. Differential diagnosis includes eosinophilic / allergic bronchopneumopathy versus infectious bronchitis such as viral, bacterial, and less likely parasitic. The presence of bronchiectasis underlines the potential of chronicity and may be associated with decreased mucociliary clearance rates. Further definition by means of airway endoscopy with airway sampling could be considered in case of pertinent clinical signs.

INVOICE
 53491

DATE
 8-16-22



PATIENT

Vader Hinson

SPECIES

Canine

BREED

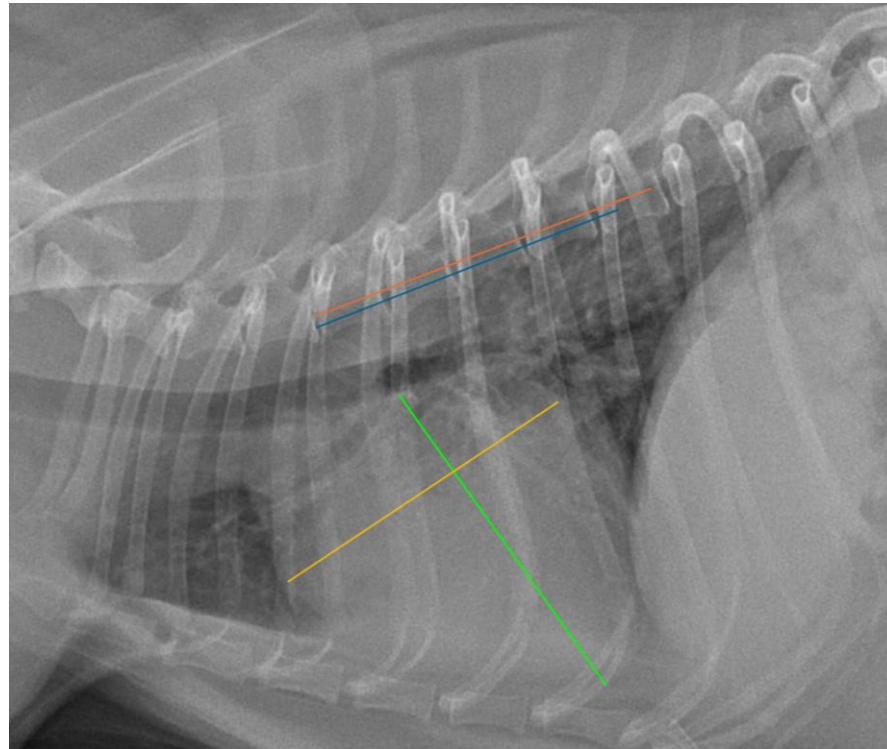
Yorkie

SEX

Male Neutered

AGE

11 Years



INTERPRETED BY

Nele Eley, DVM
Dr. med. Vet. DipECVDI

The information and recommendations provided are based on the images presented by the referring veterinarian/sonographer. No evaluation can be communicated regarding pathology that was not visible in the image/video clips provided.

HOSPITAL NAME

Companion Animal
Clinic

Thank you for this referral. If the clinical or image interpretation does not parallel your findings or if I can be of any further assistance please contact me.

REFERRING VET

Varinia Acosta

Nele Eley, DVM, Dr. med. vet., DipECVDI
European Specialist in Veterinary Diagnostic Imaging, Cert. Radiology,
Senior lecturer University of Giessen, Germany, Veterinary Faculty, Department of Radiology
Nele.Eley@sonopath.com

INVOICE

53491

DATE

8-16-22