



PATIENT

Lori VanHassel

PRESENTING CLINICAL SIGNS

Honking cough, was heartworm +, and was treated, suspect collapsing trachea.

SPECIES

Canine

RADIOGRAPHIC STUDY OF THE THORAX

Right/left lateral and ventrodorsal views of the thorax totaling 3 images available for review.

BREED

Chihuahua

RADIOGRAPHIC FINDINGS

The degree of pulmonary inflation is fair on all available images. A mild caudodorsally accentuated bronchointerstitial lung pattern is noted.

SEX

Female Spayed

No evidence of right heart or main pulmonary artery enlargement is seen. The vertebral heart score is 10.

Moderate collapse of the cervical trachea is seen on the right lateral view. Minimal collapse of the cervical trachea is present on the left lateral view. The intrathoracic trachea and mainstem bronchi present no evidence of collapse.

AGE

6 Years

There is no evidence of mediastinal widening.

The liver is relatively small in size.

Mild gastric aerophagia is noted.

INTERPRETED BY

Nele Eley, DVM
Dr. med. Vet. DipECVDI

RADIOGRAPHIC DIAGNOSIS

- Normal radiographic presentation of the cardiac silhouette and main pulmonary artery.
- Dynamic cervical tracheal disease.
- Caudodorsally accentuated bronchointerstitial lung pattern.

HOSPITAL NAME

Ramapo Valley
Animal Hospital

INTERPRETATION OF THE FINDINGS & FURTHER RECOMMENDATIONS

The radiographic study confirms the suspicion of dynamic tracheal disease. A collapsing cervical trachea is noted with a varying degree of collapse between the right and left lateral views.

REFERRING VET

Dr. Manohar Katara

Note the presence of a mild caudodorsally accentuated bronchointerstitial lung pattern which may be enhanced by the poor pulmonary inflation. Differential diagnosis includes residual bronchopneumopathy of the prior lung worm infection versus active bronchopneumopathy versus dystelectasis versus noncardiogenic pulmonary edema. Clinical significance is uncertain.

INVOICE

53518

DATE

8-16-22



PATIENT

Lori VanHassel

SPECIES

Canine

BREED

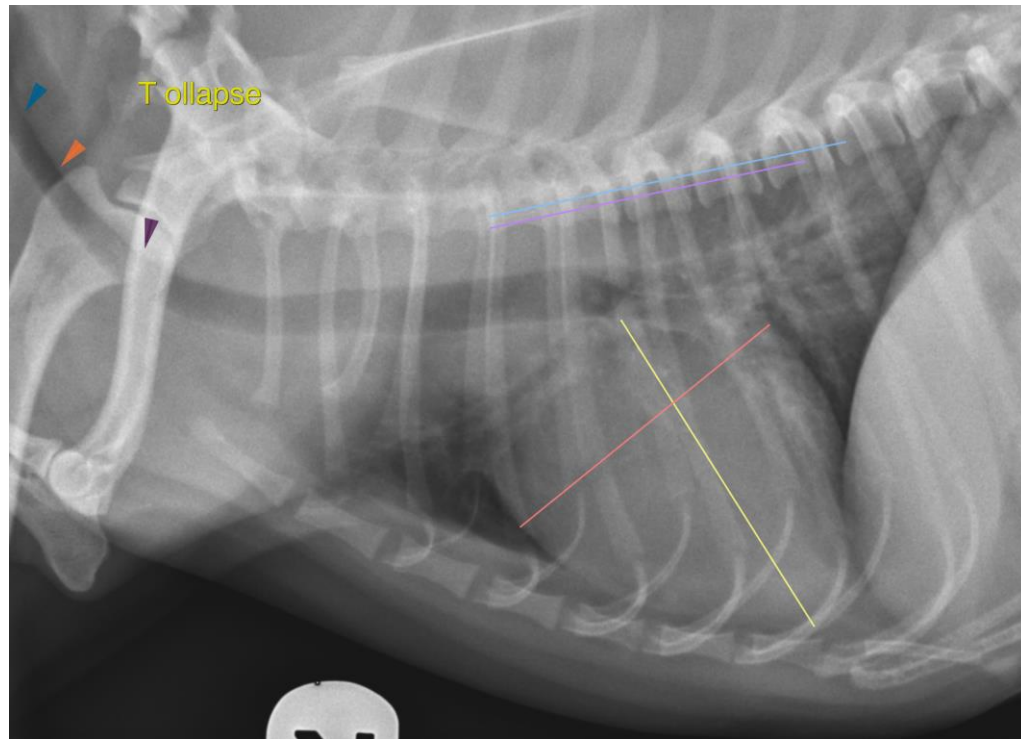
Chihuahua

SEX

Female Spayed

AGE

6 Years



INTERPRETED BY

Nele Eley, DVM
Dr. med. Vet. DipECVDI

The information and recommendations provided are based on the images presented by the referring veterinarian/sonographer. No evaluation can be communicated regarding pathology that was not visible in the image/video clips provided.

Thank you for this referral. If the clinical or image interpretation does not parallel your findings or if I can be of any further assistance please contact me.

HOSPITAL NAME

Ramapo Valley
Animal Hospital

Nele Eley, DVM, Dr. med. vet., DipECVDI
European Specialist in Veterinary Diagnostic Imaging, Cert. Radiology,
Senior lecturer University of Giessen, Germany, Veterinary Faculty, Department of Radiology
Nele.Eley@sonopath.com

REFERRING VET

Dr. Manohar Katara

INVOICE

53518

DATE

8-16-22