

**PATIENT**

Lola Dimitrovski

PRESENTING CLINICAL SIGNS

Intermittent limping of right forelimb for 2 months. Tickborne disease negative, no obvious focal area of pain found on exam. Limping was responsive to NSAID therapy. Not currently on any medications.

SPECIES

Canine

RADIOGRAPHIC STUDY OF THE RIGHT CARPUS, RIGHT ELBOW, & RIGHT SHOULDER

Mediolateral view of the right carpus and elbow, mediolateral view of the right shoulder, and craniocaudal view of both forearms totaling 4 images available for review.

BREED

Spaniel Mix

RADIOGRAPHIC FINDINGS

A 10 x 5mm sized ovoid mineralized structure is seen cranial and distal to the right greater humeral tubercle. There appears to be increased opacity within the intertubercular groove of the biceps tendon in the proximal right humerus however this is superimposed onto the tracheal cartilages. The periarticular margins present smooth with no evidence of osteophytosis.

SEX

FS

The right elbow and right and left carpus present within age related normal limits.

AGE

7

RADIOGRAPHIC DIAGNOSIS

- Suspect mineralizing right supraspinatus tendinopathy and chronic right biceps tenosynovitis.

INTERPRETATION OF THE FINDINGS & FURTHER RECOMMENDATIONS

The radiographic findings suggest presence of a large mineralization within the anatomic position of the right supraspinatus tendon. There also is radiographic evidence of osseous remodeling within the intertubercular groove of the biceps tendon suggesting potential for chronic biceps tendinopathy which may occur as a primary entity or secondary to biceps impingement. Further definition by means of shoulder ultrasound or an MRI could be considered in case of paralleling clinical signs.

INTERPRETED BY

Nele Eley, DVM
Dr. med. Vet. DipECVCI

HOSPITAL NAME

Rockaway Animal
Hospital

REFERRING VET

Dr. Kahn

INVOICE

53497

DATE

8-16-22



PATIENT

Lola Dimitrovski

SPECIES

Canine

BREED

Spaniel Mix

SEX

FS

AGE

7

INTERPRETED BY

Nele Eley, DVM
Dr. med. Vet. DipECVDI

HOSPITAL NAME

Rockaway Animal
Hospital

REFERRING VET

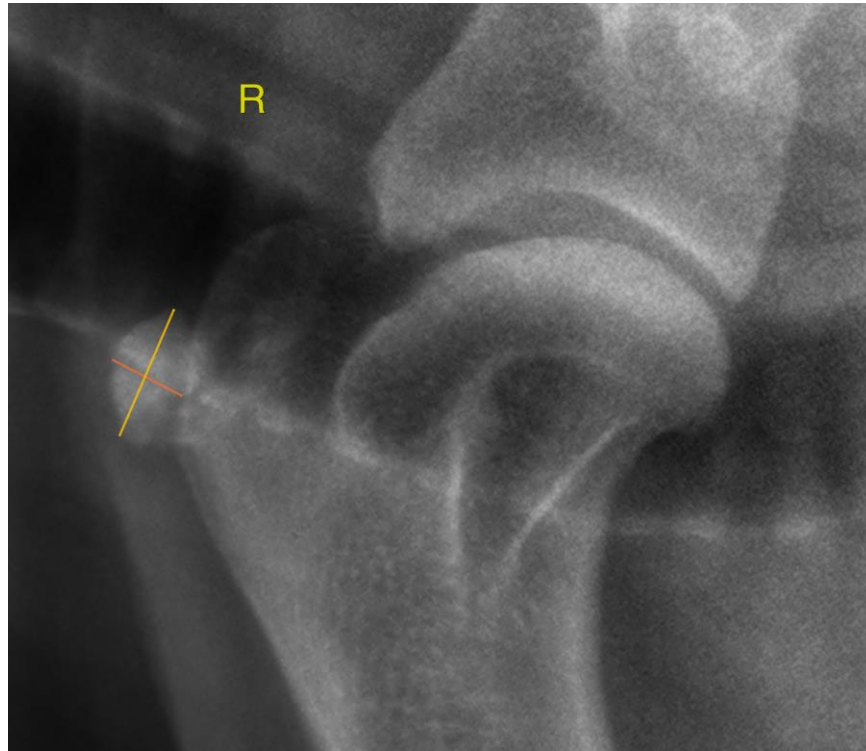
Dr. Kahn

INVOICE

53497

DATE

8-16-22



The information and recommendations provided are based on the images presented by the referring veterinarian/sonographer. No evaluation can be communicated regarding pathology that was not visible in the image/video clips provided.

Thank you for this referral. If the clinical or image interpretation does not parallel your findings or if I can be of any further assistance please contact me.

Nele Eley, DVM, Dr. med. vet., DipECVDI
European Specialist in Veterinary Diagnostic Imaging, Cert. Radiology,
Senior lecturer University of Giessen, Germany, Veterinary Faculty, Department of Radiology
Nele.Eley@sonopath.com