



**PATIENT**

Izzy Sparkle Han

**PRESENTING CLINICAL SIGNS**

rads to submit: acute onset LF lameness after being bumped by another dog. swelling notable just below the elbow- pain elicited. r/o soft tissue trauma

**SPECIES**

Canine

**RADIOGRAPHIC STUDY OF THE LEFT FRONT LIMB**

2 mediolateral views of the left elbow and 1 craniocaudal view of both forearms totaling 3 images available for review in jpeg format.

**BREED**

Yorkshire Terrier

Only jpg images were submitted. The transformation from DICOM to jpg only allows for limited manipulation of the image. For the best possible results, we suggest submitting DICOM images in the future. Please do not hesitate to contact us should you need any help with the submission process.

**SEX**

Spayed Female

**RADIOGRAPHIC FINDINGS**

The radiographic presentation of the left elbow is within normal limits. No evidence of traumatic osseous injury and no evidence of elbow arthropathy is seen.

**AGE**

9 Years

Mild soft tissue swelling medial and distal to the left elbow cannot be ruled out however the radiographic appearance may also be due to asymmetric position between the right and left front limb.

The right and left carpus present within normal limits.

**INTERPRETED BY**

Nele Eley, DVM  
Dr. med. Vet. DipECVDI

**RADIOGRAPHIC DIAGNOSIS**

- Normal radiographic findings of the left elbow.

**HOSPITAL NAME**

Tenafly Vet Center

**INTERPRETATION OF THE FINDINGS & FURTHER RECOMMENDATIONS**

No evidence of osseous injury or arthropathy can be identified in the radiographic study of the left elbow. Mild soft tissue swelling may be present medial and distal to the left elbow joint. This, however, requires clinical correlation since the positioning of the left and right forearm is lightly different which may influence the radiographic appearance of the soft tissues.

**REFERRING VET**

Marcela Salas

**INVOICE**

53494

**DATE**

8-16-22



**PATIENT**

Izzy Sparkle Han

**SPECIES**

Canine

**BREED**

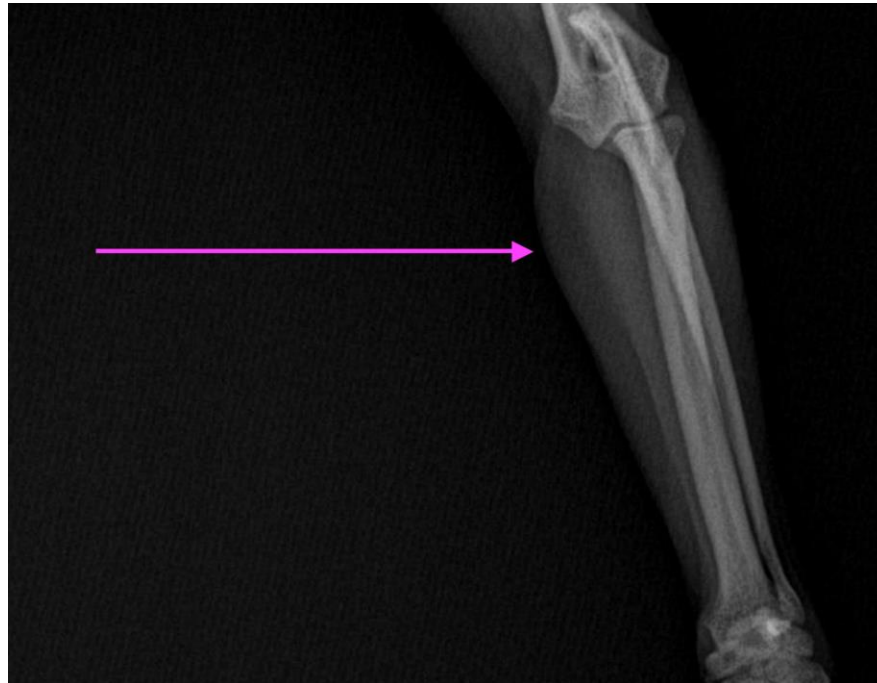
Yorkshire Terrier

**SEX**

Spayed Female

**AGE**

9 Years



**INTERPRETED BY**

Nele Eley, DVM  
Dr. med. Vet. DipECVDI

The information and recommendations provided are based on the images presented by the referring veterinarian/sonographer. No evaluation can be communicated regarding pathology that was not visible in the image/video clips provided.

Thank you for this referral. If the clinical or image interpretation does not parallel your findings or if I can be of any further assistance please contact me.

**HOSPITAL NAME**

Tenafly Vet Center

**Nele Eley**, DVM, Dr. med. vet., DipECVDI  
European Specialist in Veterinary Diagnostic Imaging, Cert. Radiology,  
Senior lecturer University of Giessen, Germany, Veterinary Faculty, Department of Radiology  
Nele.Eley@sonopath.com

**REFERRING VET**

Marcela Salas

**INVOICE**

53494

**DATE**

8-16-22