

**PATIENT**

Brie Stenman

PRESENTING CLINICAL SIGNS

TPLO surgery July 14th 2021. Slipped two weeks after surgery, and has been non-weight bearing and toe touching since. 4 weeks post surgery at this time. Concerned for meniscal or other soft tissue injury.

SPECIES

Canine

ULTRASONOGRAPHIC STUDY OF THE MEDIAL MENISCUS

5 loops of the medial meniscus and 1 loop of the patella ligament and infrapatellar region are available for review. Laterality not specified.

BREED

Shepherd Mix

ULTRASONOGRAPHIC FINDINGS

Collateral ligament thickening and ill-defined surface of the medial meniscus are seen.

SEX

Female

There is a vertical hypoechoic line within the mid to caudal portion of the medial meniscus which appears to extend up to the meniscal surface.

ULTRASONOGRAPHIC DIAGNOSIS

- Medial meniscal injury with synovialitis and collateral ligament desmitis.

AGE

2

INTERPRETATION OF THE FINDINGS & FURTHER RECOMMENDATIONS

The ultrasonographic findings suggest presence of medial meniscal injury with concurrent medial collateral ligament desmitis and synovialitis. The type and severity of the meniscal injury cannot be predicted ultrasonographically and the meniscal tissue appears to be in situ during the ultrasonographic examination. Consider arthroscopic or arthrotomic revision of the medial meniscus.

INTERPRETED BY

Nele Eley, DVM
Dr. med. Vet. DipECVDI

HOSPITAL NAME

Marda Loop
Veterinary Centre

REFERRING VET

Dr. Sarah Pedersen

INVOICE

46984

DATE

8-16-21



PATIENT

Brie Stenman

SPECIES

Canine

BREED

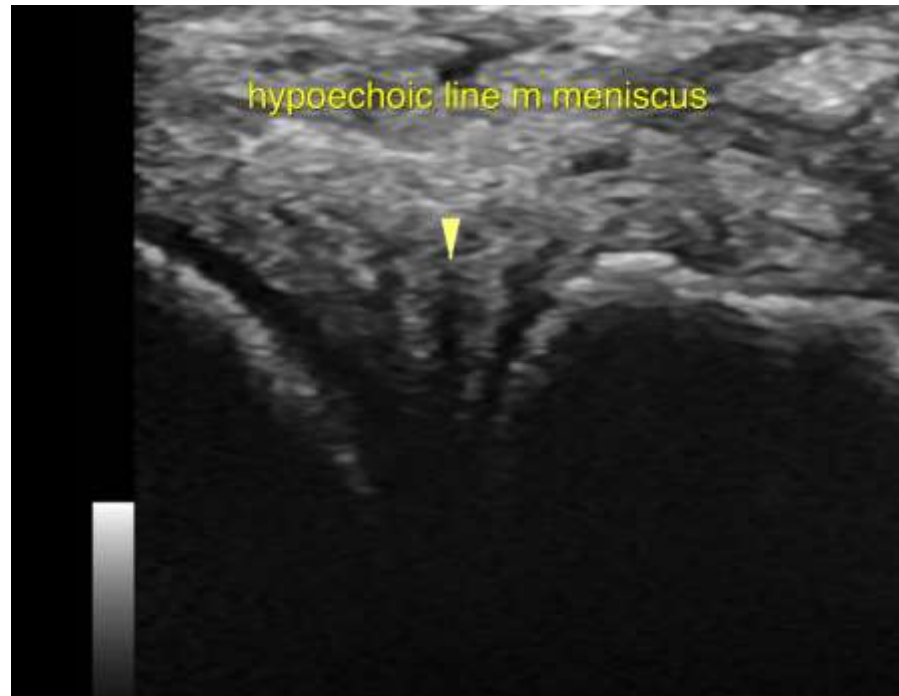
Shepherd Mix

SEX

Female

AGE

2



INTERPRETED BY

Nele Eley, DVM
Dr. med. Vet. DipECVDI

The information and recommendations provided are based on the images presented by the referring veterinarian. No evaluation can be communicated regarding pathology that was not visible in the image/video clips provided.

Thank you for this referral. If the clinical or image interpretation does not parallel your findings or if I can be of any further assistance please contact me.

HOSPITAL NAME

Marda Loop
Veterinary Centre

Nele Eley, DVM, Dr. med. vet., DipECVDI
European Specialist in Veterinary Diagnostic Imaging, Cert. Radiology,
Senior lecturer University of Giessen, Germany, Veterinary Faculty, Department of Radiology
Nele.Eley@sonopath.com

REFERRING VET

Dr. Sarah Pedersen

INVOICE

46984

DATE

8-16-21