



PATIENT

Penny Maybach

PRESENTING CLINICAL SIGNS

Staging following excision of complex ductal papillary mammary carcinoma. Pt also has dilated cardiomyopathy and is on pimobendan and benazepril.

SPECIES

Canine

RADIOGRAPHIC STUDY OF THE THORAX

Right/left lateral and ventrodorsal views of the thorax totaling 6 images available for review.

BREED

Golden Retriever

RADIOGRAPHIC FINDINGS

The vertebral heart score is 9.4. No evidence of cardiomegaly or congestive heart failure is seen.

Course and width of the trachea are considered within normal limits.

SEX

Spayed Female

The lung presents a mild generalized bronchial lung pattern. Occasional pulmonary osteomas are seen. There is no evidence of pulmonary nodules or masses.

No evidence of mediastinal widening is noted.

AGE

6 Years

The thoracic boundaries present within normal limits.

RADIOGRAPHIC DIAGNOSIS

- No evidence of pulmonary metastatic disease.
- Normal radiographic presentation of the cardiac silhouette.

INTERPRETED BY

Nele Eley, DVM
Dr. med. Vet. DipECVDI

INTERPRETATION OF THE FINDINGS & FURTHER RECOMMENDATIONS

The radiographic study reveals no evidence of cardiomegaly and no evidence of pulmonary metastatic disease. The findings are considered within age related normal limits at this point.

HOSPITAL NAME

Northshore
Veterinary Hospital

REFERRING VET

Sophie Lee, DVM

INVOICE

53471

DATE

8-15-22



PATIENT

Penny Maybach

SPECIES

Canine

BREED

Golden Retriever

SEX

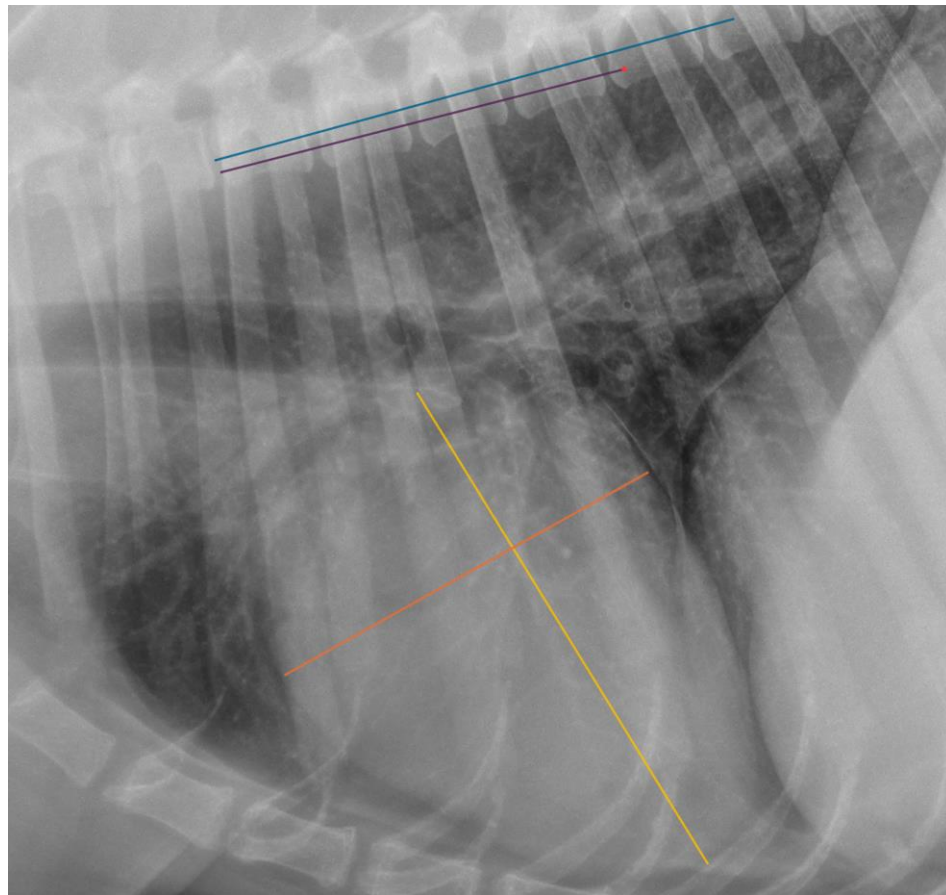
Spayed Female

AGE

6 Years

INTERPRETED BY

Nele Eley, DVM
Dr. med. Vet. DipECVDI



HOSPITAL NAME

Northshore
Veterinary Hospital

REFERRING VET

Sophie Lee, DVM

INVOICE

53471

DATE

8-15-22

The information and recommendations provided are based on the images presented by the referring veterinarian/sonographer. No evaluation can be communicated regarding pathology that was not visible in the image/video clips provided.

Thank you for this referral. If the clinical or image interpretation does not parallel your findings or if I can be of any further assistance please contact me.

Nele Eley, DVM, Dr. med. vet., DipECVDI
European Specialist in Veterinary Diagnostic Imaging, Cert. Radiology,
Senior lecturer University of Giessen, Germany, Veterinary Faculty, Department of Radiology
Nele.Eley@sonopath.com