



**PATIENT**

Jack Daniels Swan

**PRESENTING CLINICAL SIGNS**

Pt presents with dry cough starting over the weekend and has a history of a heart murmur.

**SPECIES**

Canine

**RADIOGRAPHIC STUDY OF THE THORAX**

Right/left lateral and ventrodorsal views of the thorax totaling 5 images available for review.

**BREED**

Toy Poodle Mix

**RADIOGRAPHIC FINDINGS**

Severe left sided cardiomegaly with a vertebral heart score of 12.8 is noted. There is severe left atrial tenting with splitting of the mainstem bronchi and double opacity sign in the orthogonal view. Dilatation of the pulmonary vessels is noted.

**SEX**

Male Neutered

A mild diffuse interstitial pattern is seen in the perihilar region of the right caudal lung lobe in the orthogonal view. The remainder of the lung presents within normal limits.

Course and width of the trachea are considered within normal limits.

Mild generalized enlargement of the liver is seen.

**AGE**

10 Years, 9 Months

**RADIOGRAPHIC DIAGNOSIS**

- Severe left sided cardiomegaly with left atrial enlargement.
- Suspect emerging cardiogenic pulmonary edema.
- Mild generalized hepatomegaly.

**INTERPRETED BY**

Nele Eley, DVM  
Dr. med. Vet. DipECVDI

**INTERPRETATION OF THE FINDINGS & FURTHER RECOMMENDATIONS**

The radiographic study reveals severe left sided cardiomegaly. Left atrial enlargement is noted as well as a vascular lung pattern. The interstitial increase in opacity in the right caudal lung lobe suggests emerging cardiogenic pulmonary edema. The use of diuretics appears to be indicated. A full cardiac echo is recommended if not performed already in order to adjust the medication accordingly.

**HOSPITAL NAME**

Ahwatukee Commons  
Veterinary Hospital

Differential diagnosis for the hepatomegaly includes endocrine, metabolic, and vacuolar hepatopathy. Diffuse infiltration with inflammatory cells, infectious disease, or diffuse neoplasia cannot be ruled out entirely as differential diagnoses.

**REFERRING VET**

Dr. Rebecca R.  
Housley

**INVOICE**

53479

**DATE**

8-15-22



**PATIENT**

Jack Daniels Swan

**SPECIES**

Canine

**BREED**

Toy Poodle Mix

**SEX**

Male Neutered

**AGE**

10 Years, 9 Months

**INTERPRETED BY**

Nele Eley, DVM  
Dr. med. Vet. DipECVDI

**HOSPITAL NAME**

Ahwatukee Commons  
Veterinary Hospital

**REFERRING VET**

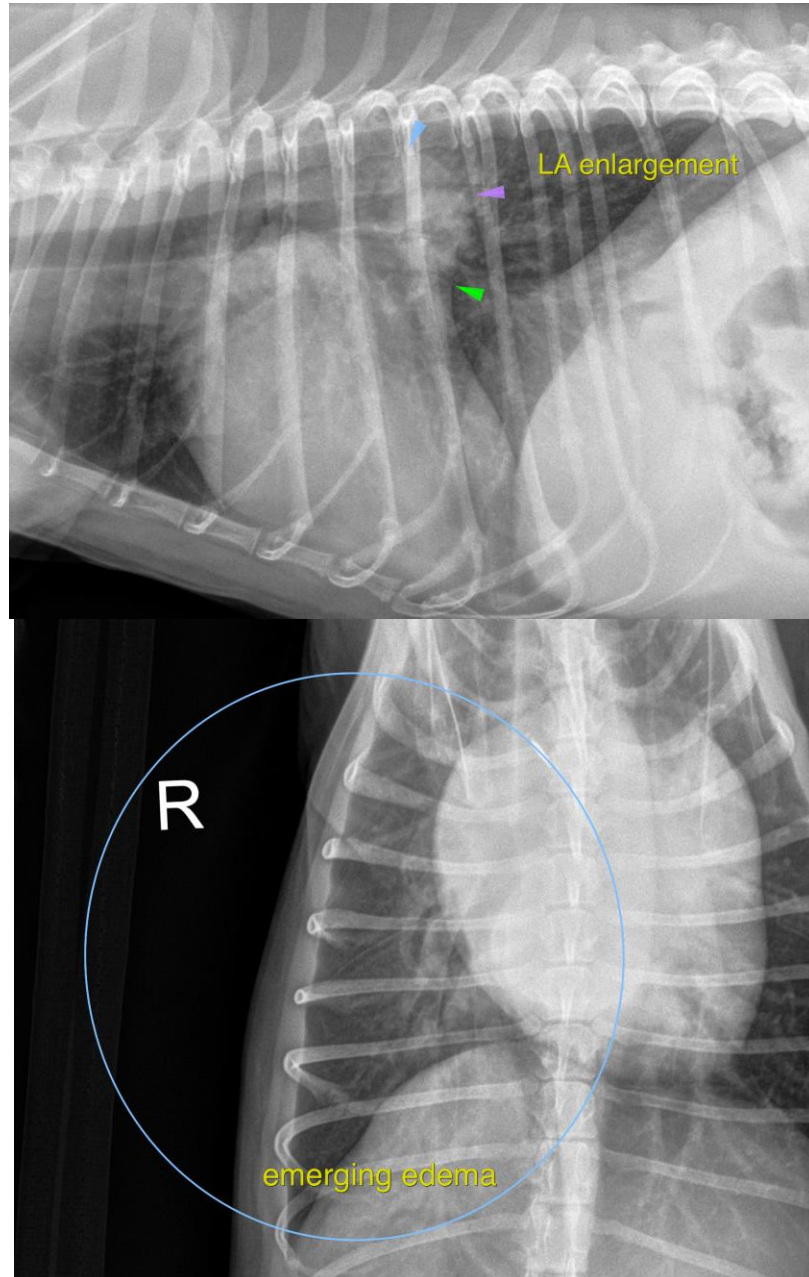
Dr. Rebecca R.  
Housley

**INVOICE**

53479

**DATE**

8-15-22





**PATIENT**

Jack Daniels Swan

**SPECIES**

Canine

**BREED**

Toy Poodle Mix

**SEX**

Male Neutered

**AGE**

10 Years, 9 Months

**INTERPRETED BY**

Nele Eley, DVM  
Dr. med. Vet. DipECVDI

**HOSPITAL NAME**

Ahwatukee Commons  
Veterinary Hospital

**REFERRING VET**

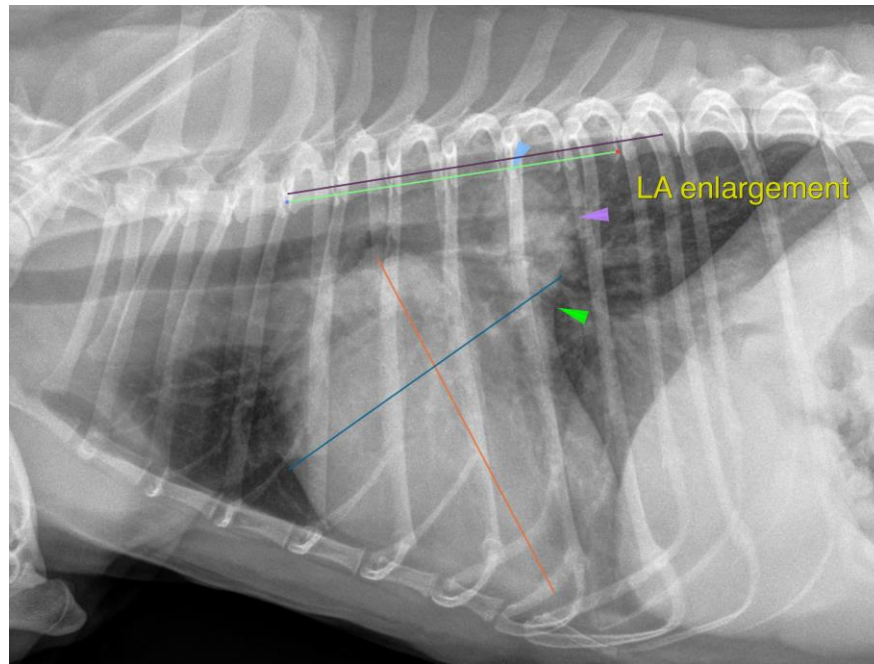
Dr. Rebecca R.  
Housley

**INVOICE**

53479

**DATE**

8-15-22



The information and recommendations provided are based on the images presented by the referring veterinarian/sonographer. No evaluation can be communicated regarding pathology that was not visible in the image/video clips provided.

Thank you for this referral. If the clinical or image interpretation does not parallel your findings or if I can be of any further assistance please contact me.

**Nele Eley**, DVM, Dr. med. vet., DipECVDI  
European Specialist in Veterinary Diagnostic Imaging, Cert. Radiology,  
Senior lecturer University of Giessen, Germany, Veterinary Faculty, Department of Radiology  
Nele.Eley@sonopath.com