



PATIENT PRESENTING CLINICAL SIGNS

PATIENT
Spice Smith

SPECIES
Feline

BREED
DLH

SEX
FS

AGE
13 Years

INTERPRETED BY
Nele Eley, DVM
Dr. med. Vet. DipECVDI

HOSPITAL NAME
Southern Oregon
Veterinary Specialty
Center

REFERRING VET
Dr. Ravi Seshadri

INVOICE
53468

DATE
8-13-22

Sudden onset, dramatic and progressive swelling with bruising to the RIGHT side of the face involving the R eye, mouth and tongue for 48 to 72 hours. Presenting Complaint: acute onset facial swelling; history of pawing at face, drooling for last year Significant PE Findings: dyspnea, open mouth breathing; weakness; grade 4/6 murmur; right submandibular lymphadenopathy; cornea cloudy OD; elevated third eyelid OD; exophthalmos OD; Mucoïd ocular discharge OD; minimal debris AU; marked dental disease with multiple teeth removed; putrid smelling oral cavity; edematous frenulum and gingival tissues DDX: retrobulbar abscess; tooth root abscess; retrobulbar mass; trauma; sialoceles; allergic reaction; other Client Discussion: SWO about differentials and treatment options. P is open mouth breathing due to severe swelling around airways. Most likely differential is for retrobulbar mass or abscess but cannot rule out fistula, trauma, other. Recommend hospitalization and diagnostics including labwork and CT scan. After the CT and today's PCV, owner elected for euthanasia. Necropsy is pending. Abnormal PE/Chem/CBC/UA Results: Initial intake PCV = 31, today's PCV=12.

COMPUTED TOMOGRAPHIC STUDY OF THE HEAD

Plain and post contrast studies available for review.

COMPUTED TOMOGRAPHIC FINDINGS

A large irregular shaped and ill-defined approximately 5 x 2 cm sized hypoattenuating mass is seen in the right retrobulbar and retropharyngeal soft tissue. The mass presents central cavitation with a mostly fluid attenuating center and peripheral contrast enhancement. No evidence of aggressive osteolytic changes is seen and there is no evidence of relevant dental changes. A moderate right sided exophthalmos is noted. Saccular dilation of the right retropharyngeal vein is seen with contrast pooling on the post-contrast study.

Both tympanic bullae contain fluid attenuating material. The external auditory meatuses present within normal limits.

Moderate right sided retropharyngeal and submandibular lymphadenomegaly is noted.

There is moderate fat stranding in the right ventral neck.

Foreign material cannot be identified.

COMPUTED TOMOGRAPHIC DIAGNOSIS

- Large right sided cavitory retrobulbar mass with right sided exophthalmos and peripheral fat stranding.
- Right sided submandibular and retropharyngeal lymphadenomegaly.
- Bilateral otitis media.

INTERPRETATION OF THE FINDINGS & FURTHER RECOMMENDATIONS

Retrobulbar abscess is a primary differential diagnosis however tumor with central tumor necrosis cannot be ruled out and further definition by means of histology is recommended.

The saccular dilation of the right retropharyngeal vessel is likely due to vascular compromise



PATIENT secondary to the severe mass effect within retrobulbar, retromolar, and retropharyngeal tissues.

Spice Smith The lymph node changes suggest reactive hyperplasia, however, early metastatic disease cannot be ruled out. Correlate with the results of the necropsy/histology.

SPECIES

Feline

BREED

DLH

SEX

FS

AGE

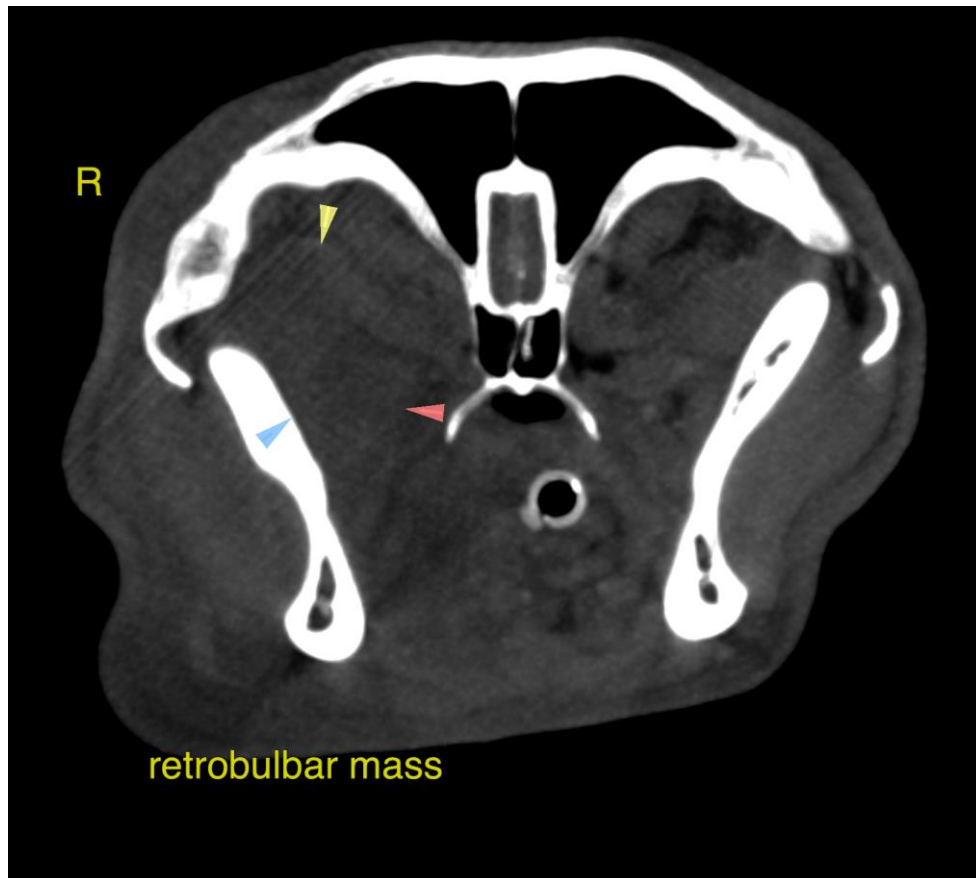
13 Years

INTERPRETED BY

Nele Eley, DVM
Dr. med. Vet. DipECVDI

HOSPITAL NAME

Southern Oregon
Veterinary Specialty
Center



REFERRING VET

Dr. Ravi Seshadri

The information and recommendations provided are based on the images presented by the referring veterinarian/sonographer. No evaluation can be communicated regarding pathology that was not visible in the image/video clips provided.

Thank you for this referral. If the clinical or image interpretation does not parallel your findings or if I can be of any further assistance please contact me.

INVOICE

53468

Nele Eley, DVM, Dr. med. vet., DipECVDI
European Specialist in Veterinary Diagnostic Imaging, Cert. Radiology,
Senior lecturer University of Giessen, Germany, Veterinary Faculty, Department of Radiology
Nele.Eley@sonopath.com

DATE

8-13-22