

PATIENT PRESENTING CLINICAL SIGNS

Monster Ferguson Intermittent limping , chronic arthritis. obese previous foreign body sx 2 weeks prior.

RADIOGRAPHIC STUDY OF THE RIGHT ELBOW

SPECIES 3 oblique craniocaudal view provided for review

Canine

RADIOGRAPHIC FINDINGS

BREED

Pit Bull X

Severe osteoarthritic changes of the right elbow are seen with large amounts of periarticular osteophytes and enthesophytes in both the lateral and medial humeral epicondyles. The subchondral bone surfaces of the elbow present sclerosis, and multiple small defects are seen in the medial and lateral humeral condyles.

RADIOGRAPHIC DIAGNOSIS

SEX

Neutered male

- End stage degenerative joint disease of the right elbow

INTERPRETATION OF FINDINGS & FURTHER RECOMMENDATIONS

AGE

6 Years

The radiographic findings are compatible with end stage degenerative joint disease of the right elbow with potential for cartilage and bone erosion in both the medial and lateral joint compartments. Enthesophytosis of the flexor and extensor origins is seen as well as multiple presumed synovial mineralizations. The underlying cause may well be medial coronoid pathology or other type of elbow dysplasia. Septic or other arthritis are thought highly unlikely as differential diagnoses.

INTERPRETED BY

Nele Eley (Ondreka),
DVM Dr. med. vet.,
DipECVDI

HOSPITAL NAME

Rockaway AH

REFERRING VET

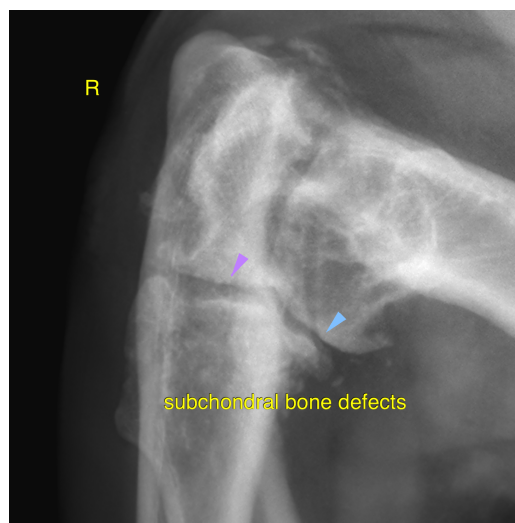
Dr. Maniar

INVOICE

24667

DATE

8/13/21





PATIENT

Monster Ferguson

The information and recommendations provided are based on the images presented by the referring veterinarian. No evaluation can be communicated regarding pathology that was not visible in the image/video clips provided.

SPECIES

Canine

Thank you for this referral. If the clinical or image interpretation does not parallel your findings or if I can be of any further assistance please contact me.

BREED

Pit Bull X

Nele Eley (Ondreka), DVM, Dr. med. vet., DipECVDI
European Specialist in Veterinary Diagnostic Imaging, Cert. Radiology,
Senior lecturer University of Giessen/Germany, Veterinary Faculty, Department of Radiology.
Nele.Eley@sonopath.com

SEX

Neutered male

AGE

6 Years

INTERPRETED BY

Nele Eley (Ondreka),
DVM Dr. med. vet.,
DipECVDI

HOSPITAL NAME

Rockaway AH

REFERRING VET

Dr. Maniar

INVOICE

24667

DATE

8/13/21