

PATIENT PRESENTING CLINICAL SIGNS

Daniel Santos Soft tissue tumor on LF leg considering amputation. MET check.

RADIOGRAPHIC STUDY OF THE THORAX

SPECIES

Right/left lateral and ventrodorsal views provided for review, totaling 3 images.

Canine

RADIOGRAPHIC FINDINGS

BREED

Spondyloses are present at T6/7 and T13/L1.

Cocker Spaniel

A mild generalized bronchointerstitial lung pattern with even distribution is noted throughout the lung. There are multiple mineral opaque pulmonary osteomas, which is an age related, incidental finding. No evidence of interstitial pulmonary nodules or masses.

SEX

The heart is of normal size and shape and there is no evidence of cardiac chamber or vascular enlargement. The pulmonary vasculature is within normal limits. The vertebral heart score is 9.2.

Neutered Male

AGE

The cranial mediastinum presents the expected soft tissue opacity. The mediastinal width is less than twice the width of the vertebral column at the same level.

10/25/06

The trachea is normal in diameter and presents the anticipated course. The luminal outline of the trachea is smooth.

INTERPRETED BY

The diaphragm is well delineated with even surface and the expected mild cranial bulging of the diaphragmatic cupola.

Nele Eley (Ondreka),
DVM Dr. med. vet.,
DipECVDI

A mild amount of gravel is seen in the gastric pylorus.

RADIOGRAPHIC DIAGNOSIS

HOSPITAL NAME

- No evidence of pulmonary metastatic disease
- No evidence of mediastinal lymphadenomegaly
- Spondyloses (incidental finding)
- Gastric gravel

Cottage Grove VC

INTERPRETATION OF FINDINGS & FURTHER RECOMMENDATIONS

REFERRING VET

The radiographic study is negative for pulmonary metastatic disease. There is no evidence of mediastinal lymphadenomegaly. The findings of the lung and bronchial tree are considered within age related normal limits. The presence of gastric gravel is likely an incidental finding due to prior oral intake of mineral opaque material. No additional signs supporting chronic gastric outflow obstruction are present radiographically.

Dr. Damewood

INVOICE

24656

DATE

8/13/21



PATIENT

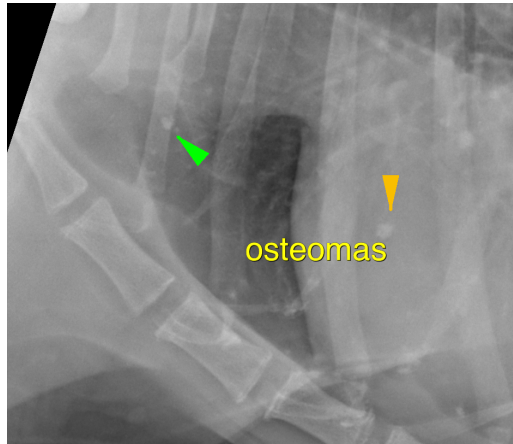
Daniel Santos

SPECIES

Canine

BREED

Cocker Spaniel



SEX

Neutered Male

The information and recommendations provided are based on the images presented by the referring veterinarian. No evaluation can be communicated regarding pathology that was not visible in the image/video clips provided.

AGE

10/25/06

Thank you for this referral. If the clinical or image interpretation does not parallel your findings or if I can be of any further assistance please contact me.

Nele Eley (Ondreka), DVM, Dr. med. vet., DipECVDI
European Specialist in Veterinary Diagnostic Imaging, Cert. Radiology,
Senior lecturer University of Giessen/Germany, Veterinary Faculty, Department of Radiology.
Nele.Eley@sonopath.com

INTERPRETED BY

Nele Eley (Ondreka),
DVM Dr. med. vet.,
DipECVDI

HOSPITAL NAME

Cottage Grove VC

REFERRING VET

Dr. Damewood

INVOICE

24656

DATE

8/13/21