

**PATIENT**

Aspen Bacon

PRESENTING CLINICAL SIGNS

1 day duration of hypersalivation/difficulty swallowing. Thoracic radiographs were normal. We did find a small ranula under the R side of the tongue, and two abscessed teeth. We wanted to check the larynx/cervical esophagus for any masses or F.B.

SPECIES

Canine

Abnormal PE/Chem/CBC/UA Results: Did not run.

COMPUTED TOMOGRAPHIC STUDY OF THE NECK

Plain and post contrast studies available for review.

BREED

Border Collie Mix

COMPUTED TOMOGRAPHIC FINDINGS

The CT presentation of the larynx is considered within normal limits. The laryngeal ventricles are filled with air. No evidence of abnormal soft tissue swelling, or foreign material is seen.

SEX

FS

The trachea presents mild flattening of its dorsal ligament without overt collapse.

Both lobes of the thyroid gland are seen and present within normal limits.

AGE

10 Years

The upper esophageal sphincter and cervical esophagus are considered within normal limits. A mild amount of gas and fluid is seen within the lumen of the esophagus. No obvious wall changes are seen.

The hypaxial and epaxial musculature present within normal limits.

INTERPRETED BY

Nele Eley, DVM
Dr. med. Vet. DipECVDI

The medial retropharyngeal lymph nodes present within normal limits.

Mild fat stranding is seen ventral of the hyoid bone and base of the tongue.

HOSPITAL NAME

Animal Health Care
Denver

COMPUTED TOMOGRAPHIC DIAGNOSIS

- Mild cellulitis ventral of the base of the tongue.
- No evidence of structural laryngeal, tracheal, or esophageal abnormality.

REFERRING VET

Cathryn Sayer

INTERPRETATION OF THE FINDINGS & FURTHER RECOMMENDATIONS

The regional cellulitis ventral of the base of the tongue is within the expected limits in a patient with a reported ranula. No evidence of other structural abnormality was noted in the CT study of the neck. The presentation of the larynx, trachea, esophagus, and surrounding musculature was all within normal limits.

INVOICE

46983

DATE

8-13-21



PATIENT

Aspen Bacon

SPECIES

Canine

BREED

Border Collie Mix

SEX

FS

AGE

10 Years

INTERPRETED BY

Nele Eley, DVM
Dr. med. Vet. DipECVDI

HOSPITAL NAME

Animal Health Care
Denver

REFERRING VET

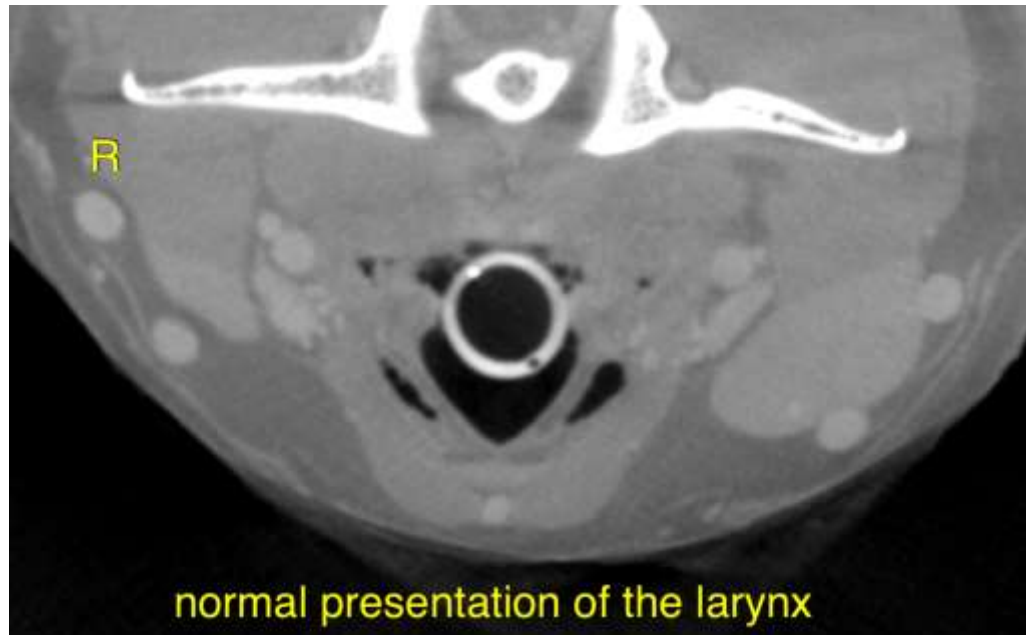
Cathryn Sayer

INVOICE

46983

DATE

8-13-21



The information and recommendations provided are based on the images presented by the referring veterinarian. No evaluation can be communicated regarding pathology that was not visible in the image/video clips provided.

Thank you for this referral. If the clinical or image interpretation does not parallel your findings or if I can be of any further assistance please contact me.

Nele Eley, DVM, Dr. med. vet., DipECVDI
European Specialist in Veterinary Diagnostic Imaging, Cert. Radiology,
Senior lecturer University of Giessen, Germany, Veterinary Faculty, Department of Radiology
Nele.Eley@sonopath.com