



PATIENT

Tank Diepeneroek

PRESENTING CLINICAL SIGNS

10 days of right side facial/eye swelling. Discharge from right side of nose and pain when opening his mouth today

SPECIES

Canine

COMPUTED TOMOGRAPHIC STUDY OF THE HEAD

Plain and post IV contrast studies available for review.

BREED

Great Dane

COMPUTED TOMOGRAPHIC FINDINGS

The tip of the nose is not included in this study.

A large ~ 7.0 cm x 3.0 cm sized cavitory lesion with fluid attenuating content and thick peripheral rim enhancement is seen in the right retrobulbar and retromolar tissue.

SEX

MN

Moderate regional soft tissue swelling with exophthalmos is seen with no evidence of foreign material.

AGE

3

The right muscles of mastication present mild generalized swelling.

A moderate amount of fluid attenuating material is seen in the right frontal sinus as well as within the right nasal cavity. No evidence of turbinate destruction or foreign material is noted.

INTERPRETED BY

Nele Eley, DVM
Dr. med. Vet. DipECVDI

The right submandibular and medial retropharyngeal lymph nodes present mild symmetric enlargement.

COMPUTED TOMOGRAPHIC DIAGNOSIS

- Right hand sided retrobulbar abscess with moderate exophthalmos and regional cellulitis.
- Right submandibular and medial retropharyngeal lymphadenomegaly compatible with reactive lymphadenitis.
- Right hand sided non-destructive rhinosinusitis.

HOSPITAL NAME

Wilvet Salem

REFERRING VET

Dr. Peterson

INTERPRETATION OF THE FINDINGS & FURTHER RECOMMENDATIONS

The CT findings are compatible with a retrobulbar abscess. Foreign material is not identified. Small pieces of migrating foreign material such as plant or other organic material may be the underlying cause of the abscessation. Abscess drainage is recommended.

INVOICE

14595ag

The rhinosinusitis may be a concurrent phenomenon secondary to the abscess and regional soft tissue inflammation.

DATE

08/12/2023

Two separate entities with non-destructive rhinosinusitis such as infectious and inflammatory with small occult pieces of foreign material cannot be ruled out entirely.



PATIENT

Tank Diepeneroek

Endoscopy with sampling could be considered in case of persisting clinical signs in conjunction with the rhinosinusitis.

SPECIES

Canine

BREED

Great Dane

SEX

MN

AGE

3

INTERPRETED BY

Nele Eley, DVM
Dr. med. Vet. DipECVDI

HOSPITAL NAME

Wilvet Salem

REFERRING VET

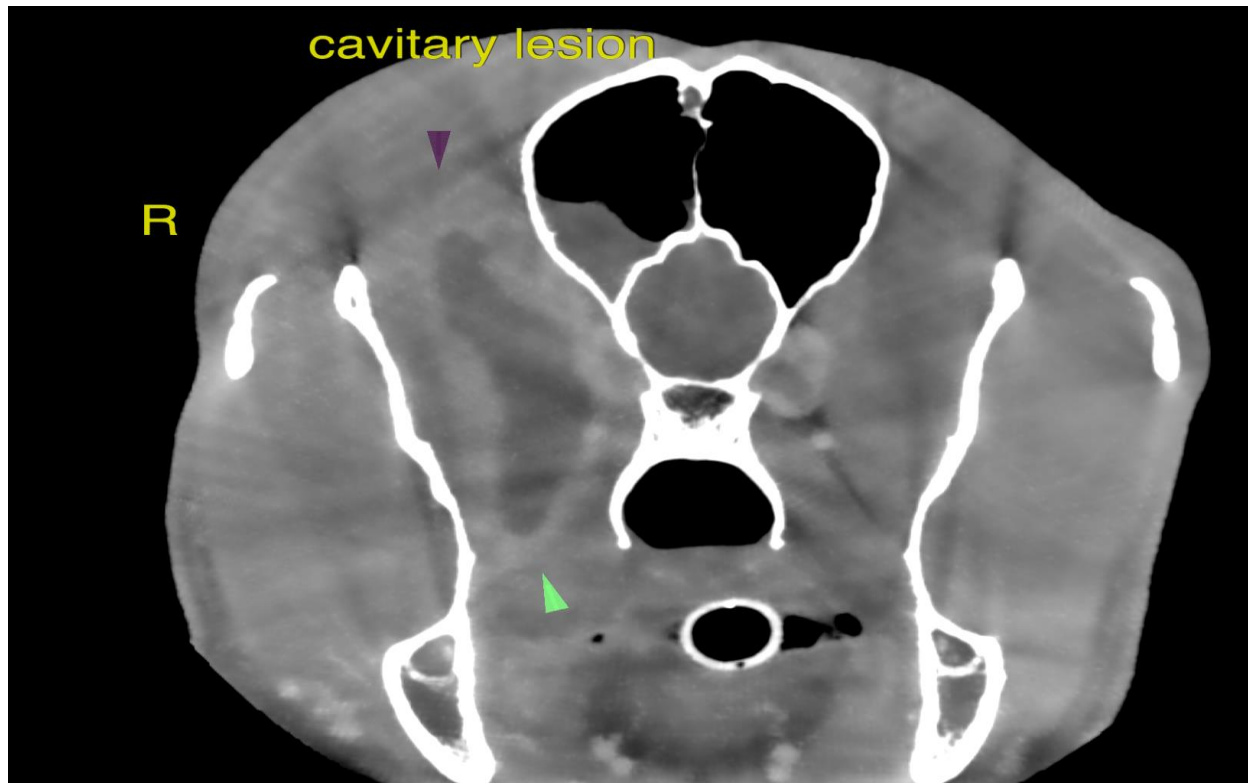
Dr. Peterson

INVOICE

14595ag

DATE

08/12/2023





PATIENT

Tank Diepeneroek

SPECIES

Canine

BREED

Great Dane

SEX

MN

AGE

3

INTERPRETED BY

Nele Eley, DVM
Dr. med. Vet. DipECVDI

HOSPITAL NAME

Wilvet Salem

REFERRING VET

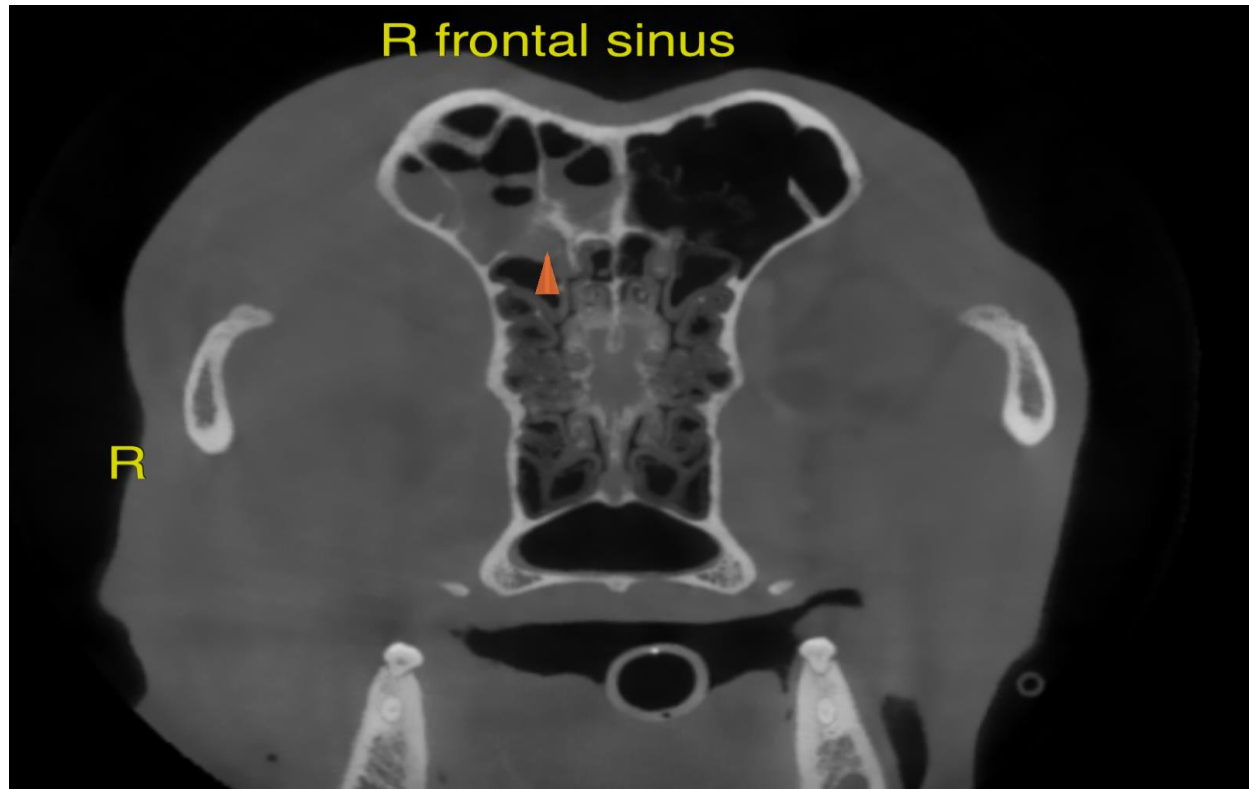
Dr. Peterson

INVOICE

14595ag

DATE

08/12/2023



The information and recommendations provided are based on the images presented by the referring veterinarian/sonographer. No evaluation can be communicated regarding pathology that was not visible in the image/video clips provided.

Thank you for this referral. If the clinical or image interpretation does not parallel your findings or if I can be of any further assistance please contact me.

Nele Eley, DVM, Dr. med. vet., DipECVDI
European Specialist in Veterinary Diagnostic Imaging, Cert. Radiology,
Senior lecturer University of Giessen, Germany, Veterinary Faculty, Department of Radiology
info@sonopath.com