

**PATIENT**

Maya Gibbs

**PRESENTING CLINICAL SIGNS**

Presents for dental cleaning. Hx reverse sneezing over past 4 months, improved with antihistamine therapy.

**SPECIES**

Canine

**COMPUTED TOMOGRAPHIC STUDY OF THE HEAD**

Plain and post IV contrast studies available for review.

**BREED**

German Shepherd  
Mix

**COMPUTED TOMOGRAPHIC FINDINGS**

The tip of the nose and dentition are fully included.

The premolar and molar teeth present within age related normal limits.

**SEX**

FS

Cystic dilation and expansion of the right nasolacrimal duct is seen. The duct is dilated within its osseous portion and measures ~20 mm in diameter. Cystic expansion of the right nasolacrimal duct communicates with the right maxillary recess which presents mild mucosal swelling. Small, mineralized structures are seen ventrally within the expanded duct. The remainder of the content is fluid attenuating and contrast negative.

**AGE**

10yr

Smooth thinning of the nasal bone is seen.

There is deviation and atrophy of the regional turbinates.

**INTERPRETED BY**

Nele Eley, DVM  
Dr. med. Vet. DipECVDI

**COMPUTED TOMOGRAPHIC DIAGNOSIS**

- Suspect dacryops of the right osseous nasolacrimal duct with dystrophic mineralization vs foreign material.

**HOSPITAL NAME**

Scottsdale Veterinary  
Clinic

**INTERPRETATION OF THE FINDINGS & FURTHER RECOMMENDATIONS**

The CT findings suggest cystic expansion of the right nasolacrimal duct compatible with dacryops. Differential diagnosis includes cyst, abscess/empyema and less likely cystic neoplasia.

**REFERRING VET**

Dr. Marissa Gibbs

The mineralized material may represent dystrophic mineralization, foreign material cannot be ruled out and is one of the most common causes of nasolacrimal duct empyema.

Regional turbinate necrosis and right maxillary sinusitis are seen concurrently.

**INVOICE**

14594ag

**DATE**

08/12/2023



**PATIENT**

Maya Gibbs

**SPECIES**

Canine

**BREED**

German Shepherd  
Mix

**SEX**

FS

**AGE**

10yr

**INTERPRETED BY**

Nele Eley, DVM  
Dr. med. Vet. DipECVDI

**HOSPITAL NAME**

Scottsdale Veterinary  
Clinic

**REFERRING VET**

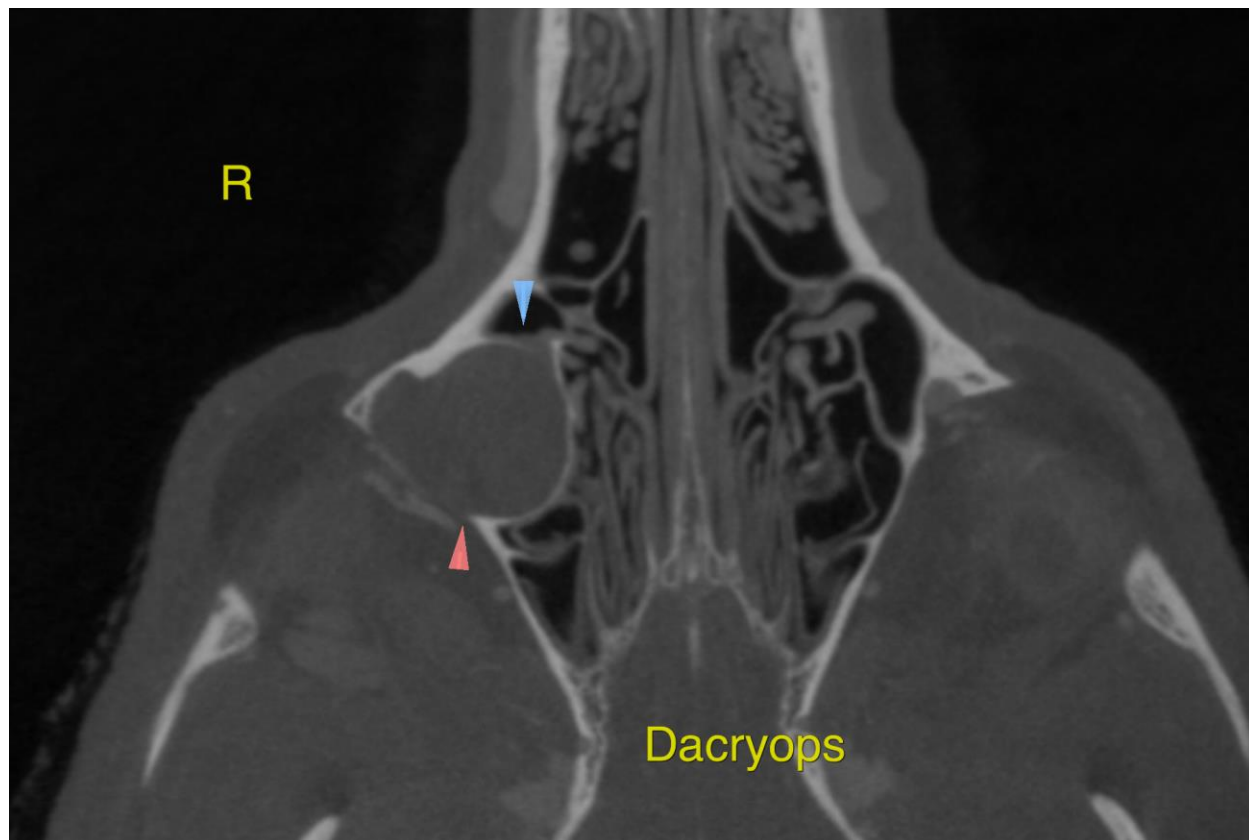
Dr. Marissa Gibbs

**INVOICE**

14594ag

**DATE**

08/12/2023





**PATIENT**

Maya Gibbs

**SPECIES**

Canine

**BREED**

German Shepherd  
Mix

**SEX**

FS

**AGE**

10yr

**INTERPRETED BY**

Nele Eley, DVM  
Dr. med. Vet. DipECVDI

**HOSPITAL NAME**

Scottsdale Veterinary  
Clinic

**REFERRING VET**

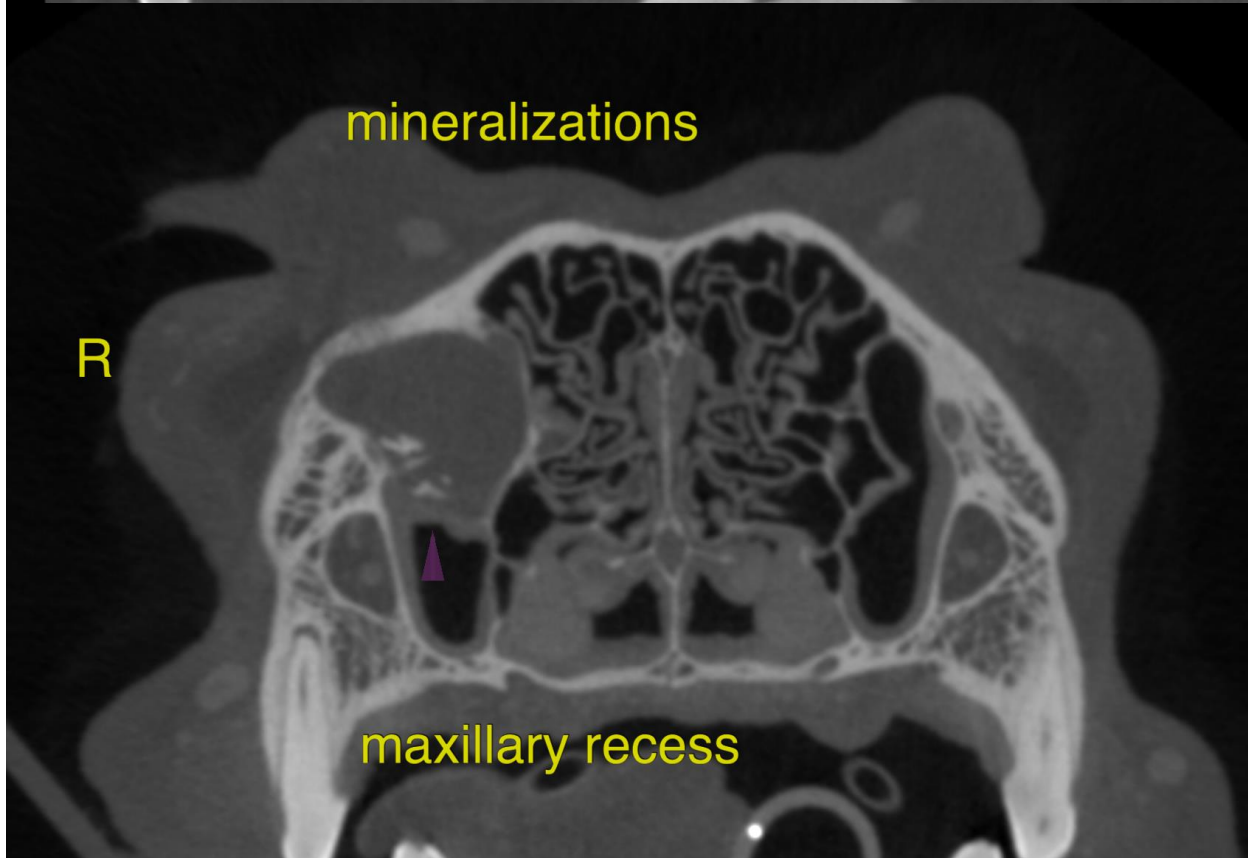
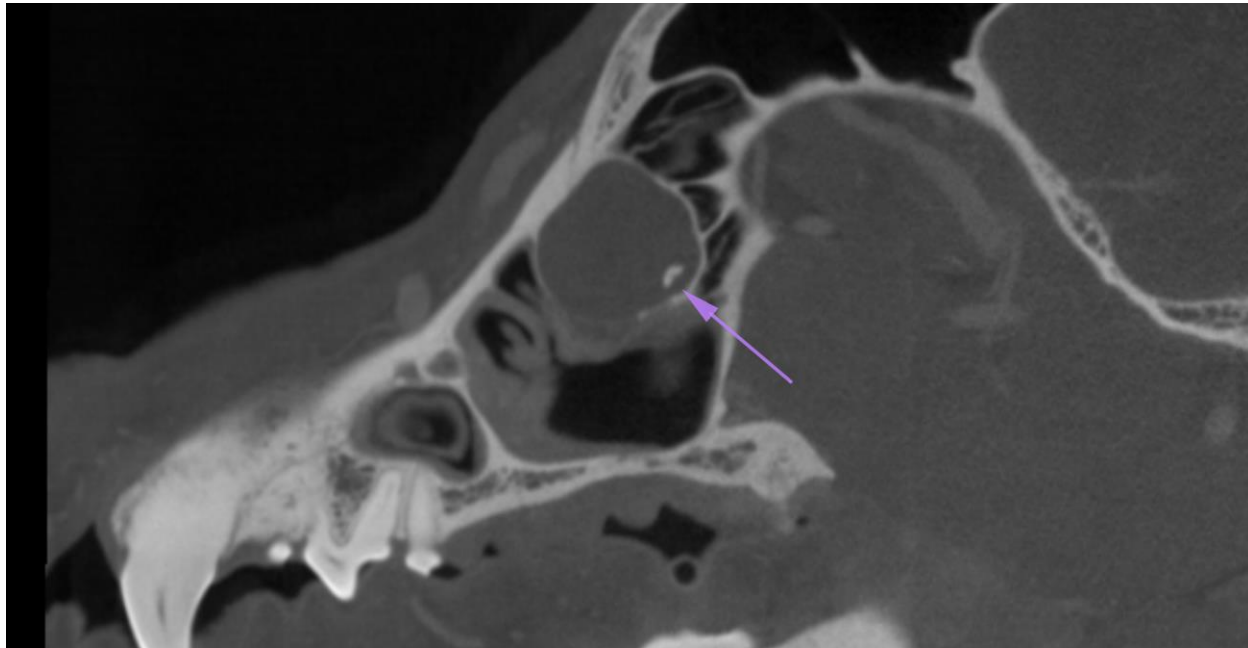
Dr. Marissa Gibbs

**INVOICE**

14594ag

**DATE**

08/12/2023





**PATIENT**

Maya Gibbs

**The information and recommendations provided are based on the images presented by the referring veterinarian/sonographer. No evaluation can be communicated regarding pathology that was not visible in the image/video clips provided.**

**SPECIES**

Canine

Thank you for this referral. If the clinical or image interpretation does not parallel your findings or if I can be of any further assistance please contact me.

**BREED**

German Shepherd  
Mix

**Nele Eley**, DVM, Dr. med. vet., DipECVDI  
European Specialist in Veterinary Diagnostic Imaging, Cert. Radiology,  
Senior lecturer University of Giessen, Germany, Veterinary Faculty, Department of Radiology  
info@sonopath.com

**SEX**

FS

**AGE**

10yr

**INTERPRETED BY**

Nele Eley, DVM  
Dr. med. Vet. DipECVDI

**HOSPITAL NAME**

Scottsdale Veterinary  
Clinic

**REFERRING VET**

Dr. Marissa Gibbs

**INVOICE**

14594ag

**DATE**

08/12/2023