

**PATIENT**Walter White
Fernicola**PRESENTING CLINICAL SIGNS**

Intermittent coughing, excessive panting

RADIOGRAPHIC STUDY OF THE THORAX**SPECIES**

Canine

Right lateral and ventrodorsal views totaling 2 images available for review.

RADIOGRAPHIC FINDINGS

Early spondylosis deformans is seen in the mid thoracic spine at T6/7.

BREED

Pitbull

The extrathoracic soft tissues present homogeneous without abnormalities.

The heart is of normal size and shape and there is no evidence of cardiac chamber or vascular enlargement. The vertebral heart score is 10.2. The pulmonary vasculature is within normal limits.

SEX

MN

The cranial mediastinum presents the expected soft tissue opacity. The mediastinal width is less than twice the width of the vertebral column at the same level.

AGE

5 Years, 11 Months

The trachea is normal in diameter and presents the anticipated course. The luminal outline of the trachea is smooth.

A moderate generalized bronchial lung pattern is seen with mild peribronchial cuffing. There also is a mild unstructured increase in interstitial background opacity of the lung.

INTERPRETED BYNele Eley, DVM
Dr. med. Vet. DipECVDI

The diaphragm is well delineated with even surface and the expected mild cranial bulging of the diaphragmatic cupola.

RADIOGRAPHIC DIAGNOSIS

- Chronic lower airway pattern.

HOSPITAL NAMERockaway Animal
Hospital**INTERPRETATION OF THE FINDINGS & FURTHER RECOMMENDATIONS**

The radiographic findings are compatible with chronic active lower airway disease. Consider eosinophilic / irritant bronchopneumopathy a potential versus infectious bronchitis such as viral, bacterial, parasitic, or protozoal. Lower airway endoscopy with airway sampling would be ideal for further definition. Alternatively, an attempt of empirical treatment for infectious bronchitis and allergic airway disease could be considered. Inhalable irritants should be removed from the patient's direct environment.

REFERRING VET

Dr. Maniar

INVOICE

46961

DATE

8-12-21



PATIENT

Walter White
Fornicola

SPECIES

Canine

BREED

Pitbull

SEX

MN

AGE

5 Years, 11 Months

INTERPRETED BY

Nele Eley, DVM
Dr. med. Vet. DipECVDI

HOSPITAL NAME

Rockaway Animal
Hospital

REFERRING VET

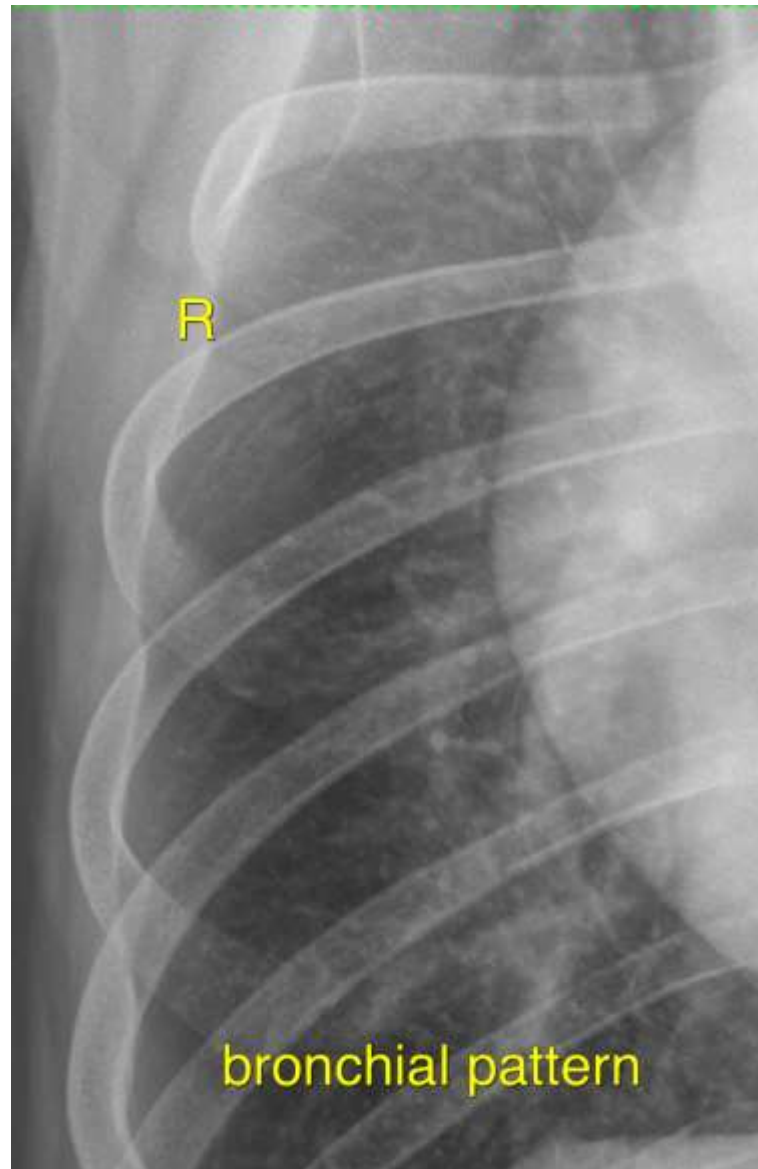
Dr. Maniar

INVOICE

46961

DATE

8-12-21



The information and recommendations provided are based on the images presented by the referring veterinarian. No evaluation can be communicated regarding pathology that was not visible in the image/video clips provided.

Thank you for this referral. If the clinical or image interpretation does not parallel your findings or if I can be of any further assistance please contact me.

Nele Eley, DVM, Dr. med. vet., DipECVDI
European Specialist in Veterinary Diagnostic Imaging, Cert. Radiology,
Senior lecturer University of Giessen, Germany, Veterinary Faculty, Department of Radiology
Nele.Eley@sonopath.com