



PATIENT PRESENTING CLINICAL SIGNS

Hulk Rivera Unproductive cough started in Feb 2021, at which time a murmur was identified (grade 3/6 L systolic). Cough tabs (dextromethorphan, Guaifenesin) seem to help. Cough has been intermittent since then, but happens frequently when playing. Sleeping more lately, recent partial hearing loss (doesn't respond consistently to owner's call)
SPECIES Abnormal PE/Chem/CBC/UA Results: Grade 5/6 L systolic murmur Mildly increased ALT (164) , ALP(287) in March 2022
 Canine

RADIOGRAPHIC STUDY OF THE THORAX

BREED Right/left lateral and ventrodorsal views of the thorax totaling 3 images available for review.
 Chinese Crested

RADIOGRAPHIC FINDINGS

SEX A 4.5 cm sized subcutaneous soft tissue mass is seen in the right ventral thoracic wall.
 MN Course and width of the trachea are considered within normal limits.

AGE The degree of pulmonary inflation is fair on all available images. A moderate generalized bronchial lung pattern and mild generalized increase in interstitial opacity is seen.

13 Years Mild generalized enlargement of the cardiac silhouette with a vertebral heart score of 11.5 is noted. Mild left atrial tenting with mild bronchial splitting is noted.

INTERPRETED BY Note the presence of moderate generalized hepatomegaly.

Nele Eley, DVM
 Dr. med. Vet. DipECVDI

RADIOGRAPHIC DIAGNOSIS

- Mild left sided cardiomegaly with left atrial enlargement.
- No evidence of congestive heart failure.
- Bronchial lung pattern.
- No evidence of dynamic tracheal disease.
- Moderate hepatomegaly.
- Soft tissue mass in the right ventral thoracic wall – consider FNA for further definition, if not performed already.

HOSPITAL NAME

Companion Animal
 Clinic

REFERRING VET

Varinia Acosta

INTERPRETATION OF THE FINDINGS & FURTHER RECOMMENDATIONS

Mild left sided cardiomegaly with left atrial enlargement and bronchial splitting is noted which may well contribute to the clinical signs of the patient. Consider further definition by means of a cardiac echo if not performed already.

INVOICE

53435

The bronchial pattern may be within age related normal limits. Low grade chronic lower airway disease such as eosinophilic bronchopneumopathy or infectious bronchitis including viral, bacterial, and less likely parasitic cannot be ruled out entirely.

DATE

8-11-22

Differential diagnosis for the hepatomegaly includes metabolic/endocrine hepatopathy, diffuse inflammatory/infectious disease, and diffuse neoplastic infiltrate. Correlate with the laboratory values to determine the necessity of further definition by means of abdominal ultrasound with eventual parenchymal sampling.



PATIENT

Hulk Rivera

SPECIES

Canine

BREED

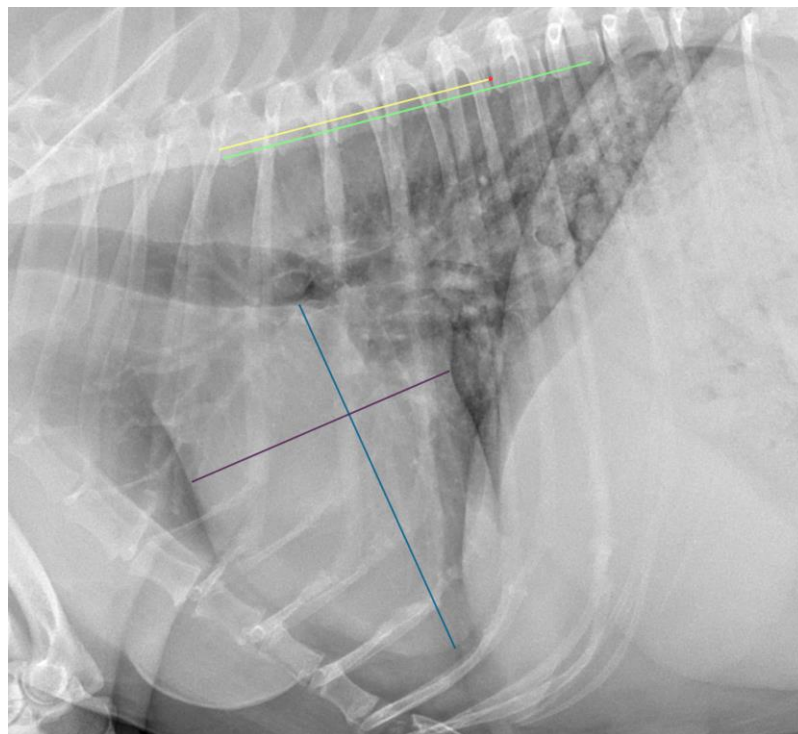
Chinese Crested

SEX

MN

AGE

13 Years



INTERPRETED BY

Nele Eley, DVM
Dr. med. Vet. DipECVDI

HOSPITAL NAME

Companion Animal
Clinic

REFERRING VET

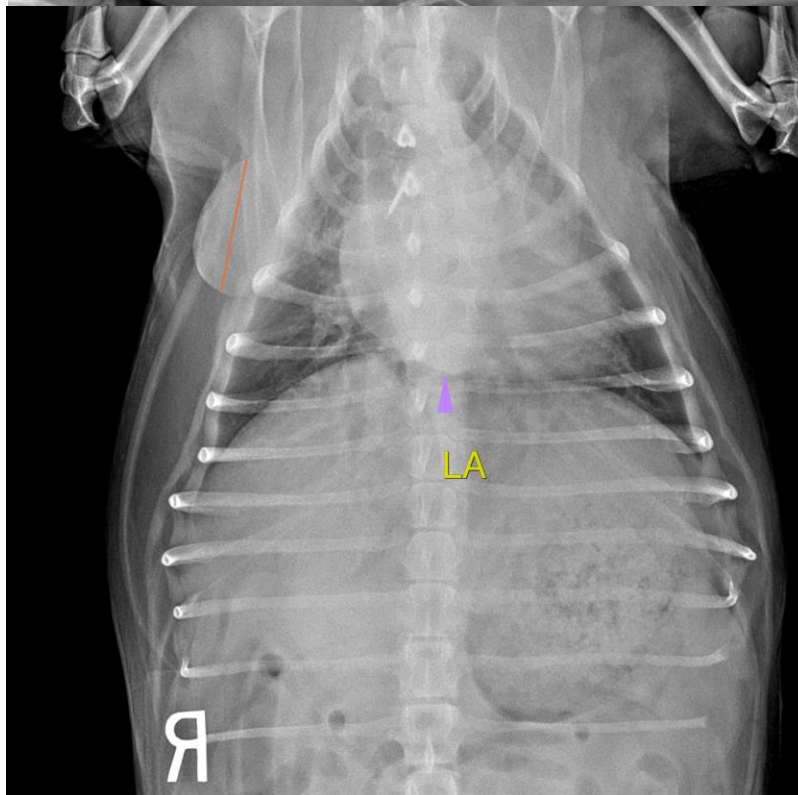
Varinia Acosta

INVOICE

53435

DATE

8-11-22





PATIENT

Hulk Rivera

The information and recommendations provided are based on the images presented by the referring veterinarian/sonographer. No evaluation can be communicated regarding pathology that was not visible in the image/video clips provided.

Thank you for this referral. If the clinical or image interpretation does not parallel your findings or if I can be of any further assistance please contact me.

SPECIES

Canine

Nele Eley, DVM, Dr. med. vet., DipECVDI
European Specialist in Veterinary Diagnostic Imaging, Cert. Radiology,
Senior lecturer University of Giessen, Germany, Veterinary Faculty, Department of Radiology
Nele.Eley@sonopath.com

BREED

Chinese Crested

SEX

MN

AGE

13 Years

INTERPRETED BY

Nele Eley, DVM
Dr. med. Vet. DipECVDI

HOSPITAL NAME

Companion Animal
Clinic

REFERRING VET

Varinia Acosta

INVOICE

53435

DATE

8-11-22