



**PATIENT PRESENTING CLINICAL SIGNS**

Bandit Brash URTI diagnosed at emergency clinic on Tuesday. No improvement since. Coughing with obvious nasal congestion and discharge, limited eating, increased lethargy, and swollen R submandibular lymph node.

**SPECIES** Abnormal PE/Chem/CBC/UA Results: Wellness Panel pending results

Feline **RADIOGRAPHIC STUDY OF THE THORAX**

Right/left lateral and ventrodorsal whole body views totaling 5 images available for review.

**BREED** Thoracic read requested.

DSH

**RADIOGRAPHIC FINDINGS**

**SEX** Layered increase in subcutaneous soft tissue opacity and swelling is noted dorsal to the thoracic spine. (Subcutaneous injection/infusion.)

Spayed Female Note the presence of thoracolumbar spondyloses.

**AGE** The ribcage is expanded with ventrally diverging intercostal spaces and barrel shaped. Wide lumbodiaphragmatic angles and flat diaphragmatic cupola is noted.

11 Years A moderate generalized bronchial lung pattern with peribronchial cuffing is seen and evenly distributed throughout the lung.

**INTERPRETED BY**

Nele Eley, DVM  
Dr. med. Vet. DipECVDI

The cardiovascular structures present within normal limits.

Course and width of the trachea present within normal limits.

There is no evidence of mediastinal widening.

**HOSPITAL NAME**

Truscott Animal  
Hospital

Extensive gastric aerophagia is seen.

**RADIOGRAPHIC DIAGNOSIS**

**REFERRING VET**

Dr. Peter Henin

- Moderate chronic generalized bronchial lung pattern with air trapping.
- Aerophagia.
- Spondyloses.
- Subcutaneous infusion.

**INVOICE**

53437

**INTERPRETATION OF THE FINDINGS & FURTHER RECOMMENDATIONS**

The radiographic study reveals active chronic lower airway disease. Allergic lower airway syndrome is a potential versus infectious bronchitis or superinfection with viral, bacterial, and less likely parasitic or protozoal microorganisms. Further definition by means of upper and lower airway endoscopy with airway sampling could be considered versus a clinical trial of treatment for upper and lower respiratory tract infection.

**DATE**

8-11-22



**PATIENT**

Bandit Brash

**SPECIES**

Feline

**BREED**

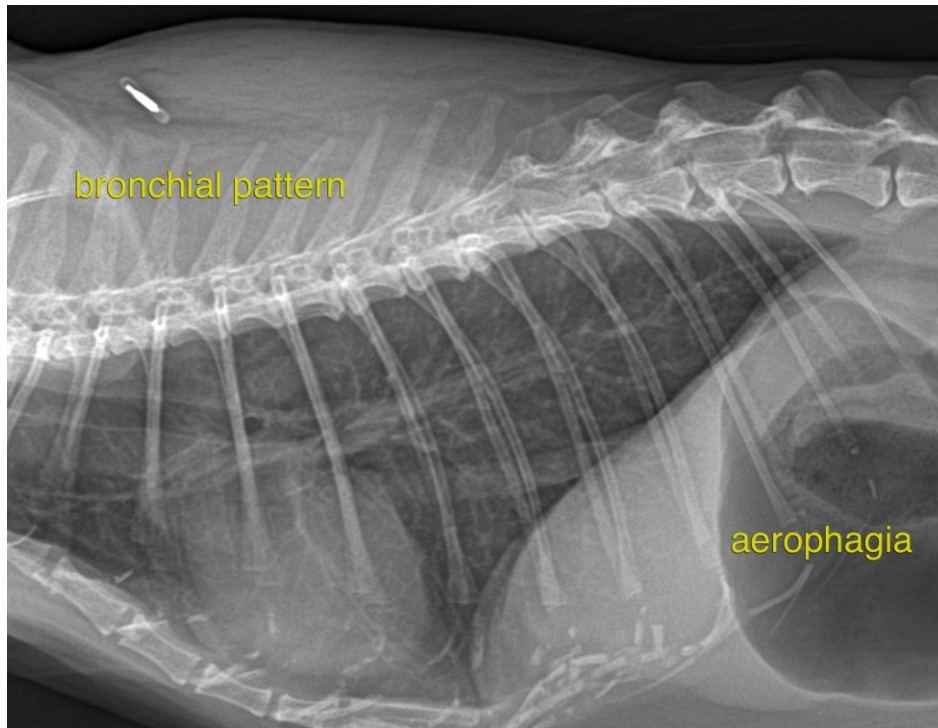
DSH

**SEX**

Spayed Female

**AGE**

11 Years



**INTERPRETED BY**

Nele Eley, DVM  
Dr. med. Vet. DipECVDI

The information and recommendations provided are based on the images presented by the referring veterinarian/sonographer. No evaluation can be communicated regarding pathology that was not visible in the image/video clips provided.

**HOSPITAL NAME**

Truscott Animal  
Hospital

Thank you for this referral. If the clinical or image interpretation does not parallel your findings or if I can be of any further assistance please contact me.

**Nele Eley**, DVM, Dr. med. vet., DipECVDI  
European Specialist in Veterinary Diagnostic Imaging, Cert. Radiology,  
Senior lecturer University of Giessen, Germany, Veterinary Faculty, Department of Radiology  
Nele.Eley@sonopath.com

**REFERRING VET**

Dr. Peter Henin

**INVOICE**

53437

**DATE**

8-11-22