



PATIENT

Koko Isaza

PRESENTING CLINICAL SIGNS

Concern for aspiration pneumonia vs underlying heart disease

SPECIES

Canine

RADIOGRAPHIC STUDY OF THE THORAX

Right/left lateral and ventrodorsal views totaling 3 images available for review.

BREED

French Bulldog

RADIOGRAPHIC FINDINGS

The radiographic presentation of the cardiac silhouette is within normal limits. No evidence of cardiomegaly is noted and there is no evidence of specific chamber enlargement as well as no evidence of cardiogenic pulmonary edema.

SEX

MN

Moderate generalized dilation of the esophagus with gas is seen. There is no evidence of esophageal foreign material.

AGE

7 Years

No evidence of a mediastinal mass is noted.

The right cranial and right middle lung lobes present a mixed alveolar interstitial infiltrate with maintained pulmonary volume accentuating their cranial and ventral portions. The remainder of the lung presents a mild generalized bronchointerstitial pattern.

Moderate gastric aerophagia is seen.

INTERPRETED BY

Nele Eley, DVM
Dr. med. Vet. DipECVDI

RADIOGRAPHIC DIAGNOSIS

- Megaesophagus with aspiration pneumonia.
- No radiographic evidence of cardiovascular pathology.
- No evidence of a mediastinal mass.
- Aerophagia.

HOSPITAL NAME

Rockaway Animal
Hospital

INTERPRETATION OF THE FINDINGS & FURTHER RECOMMENDATIONS

The radiographic findings are compatible with megaesophagus and aspiration pneumonia. There is no evidence of a mediastinal mass in terms of underlying thymoma. Differential diagnosis includes idiopathic megaesophagus as well as neuromuscular disease including myasthenia gravis and polymyositis as well as esophagitis and esophageal dysmotility and less likely Addison's disease.

REFERRING VET

Dr Ascot

INVOICE

46948

DATE

8-11-21



PATIENT

Koko Isaza

SPECIES

Canine

BREED

French Bulldog

SEX

MN

AGE

7 Years

INTERPRETED BY

Nele Eley, DVM
Dr. med. Vet. DipECVDI

HOSPITAL NAME

Rockaway Animal
Hospital

REFERRING VET

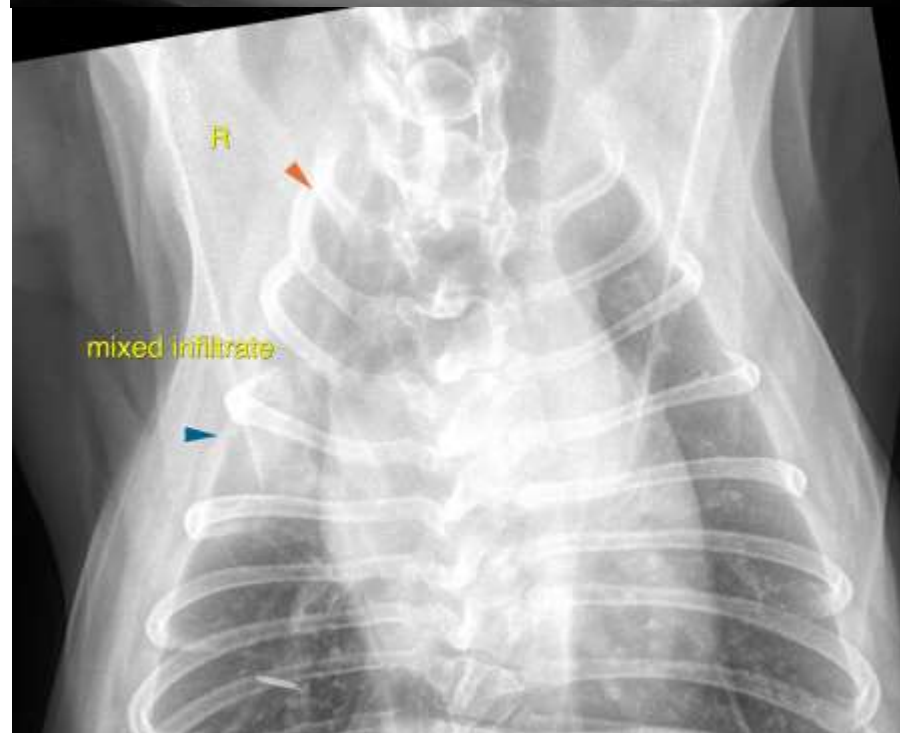
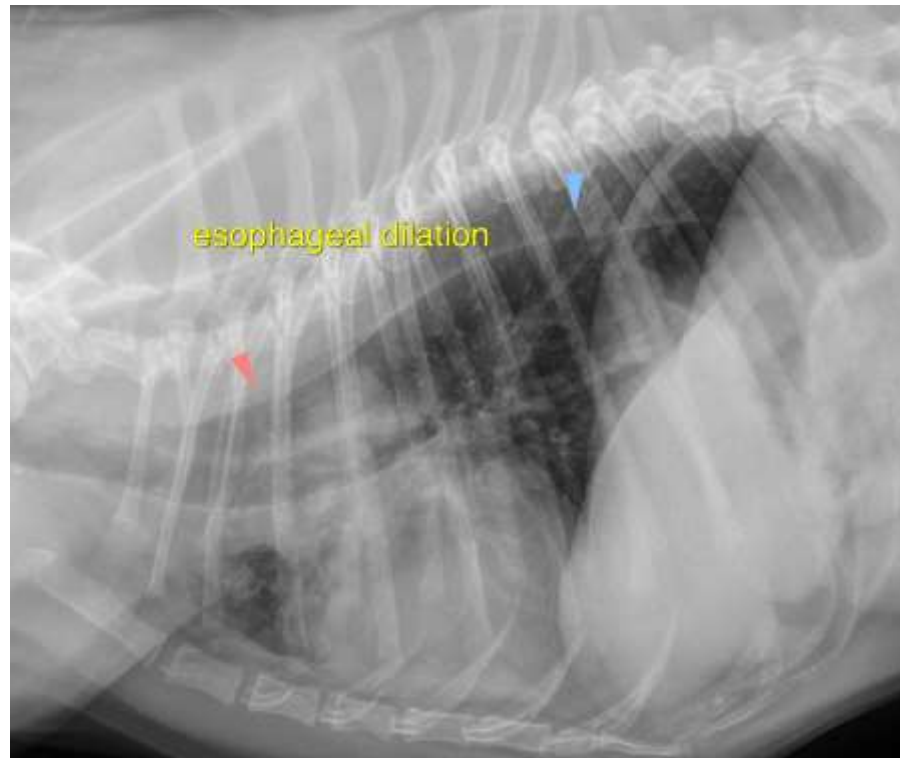
Dr Ascot

INVOICE

46948

DATE

8-11-21





PATIENT

Koko Isaza

The information and recommendations provided are based on the images presented by the referring veterinarian. No evaluation can be communicated regarding pathology that was not visible in the image/video clips provided.

SPECIES

Canine

Thank you for this referral. If the clinical or image interpretation does not parallel your findings or if I can be of any further assistance please contact me.

BREED

French Bulldog

Nele Eley, DVM, Dr. med. vet., DipECVDI
European Specialist in Veterinary Diagnostic Imaging, Cert. Radiology,
Senior lecturer University of Giessen, Germany, Veterinary Faculty, Department of Radiology
Nele.Eley@sonopath.com

SEX

MN

AGE

7 Years

INTERPRETED BY

Nele Eley, DVM
Dr. med. Vet. DipECVDI

HOSPITAL NAME

Rockaway Animal
Hospital

REFERRING VET

Dr Ascot

INVOICE

46948

DATE

8-11-21