


PATIENT PRESENTING CLINICAL SIGNS

Swirl Brooks P will hack/ cough at least once a day - single hack/ cough - never associated with exertion -Please comment on Pulmonary pattern

SPECIES RADIOGRAPHIC STUDY OF THE THORAX

Canine Right/left lateral and ventrodorsal views of the thorax totaling 3 images available for review.

RADIOGRAPHIC FINDINGS
BREED

Chihuahua

The degree of pulmonary inflation is moderate. A mild generalized bronchointerstitial lung pattern and occasional age related incidental pulmonary osteomas are noted.

There is no evidence of abnormal mediastinal widening.

SEX

Spayed Female

The trachea is undulating and course. Mild to moderate collapse of the cervical trachea is noted with redundancy of the dorsal tracheal ligament in the thoracic trachea. No concurrent bronchial collapse is seen.

AGE

10 Years 2 Months

The radiographic presentation of the cardiac silhouette is within normal limits. Vertebral heart score is 9.2.

The pulmonary vasculature presents within normal limits.

The thoracic boundaries present within normal limits.

INTERPRETED BY

Nele Eley (Ondreka),
DVM Dr. med. vet.,
DipECVDI

RADIOGRAPHIC DIAGNOSIS

- Suspect dynamic tracheal disease
- Mild generalized bronchointerstitial lung pattern
- Normal radiographic presentation of the cardiovascular structures

HOSPITAL NAME

DTLA Vets

INTERPRETATION OF FINDINGS & FURTHER RECOMMENDATIONS

The main finding appears to be the presence of radiographic changes supporting dynamic tracheal disease, which typically is secondary to chronic degenerative bronchomalacia. The mild bronchointerstitial lung pattern may be within age related normal limits. Concurrent lower airway disease such as allergic bronchopneumopathy or infectious bronchitis such as viral, bacterial, or parasitic cannot be ruled out entirely but is not necessarily the most likely potential. Further definition by means of airway endoscopy with airway sampling could be considered, which would allow for further assessment of the tracheal and laryngeal dynamics as well as to obtain samples from the airways to rule out potential concurrent lower airway disease.

REFERRING VET

Dr. Castaneda

INVOICE

44626

DATE

8/10/23



PATIENT

Swirl Brooks

SPECIES

Canine

BREED

Chihuahua

SEX

Spayed Female

AGE

10 Years 2 Months

INTERPRETED BY

Nele Eley (Ondreka),
DVM Dr. med. vet.,
DipECVDI

HOSPITAL NAME

DTLA Vets

REFERRING VET

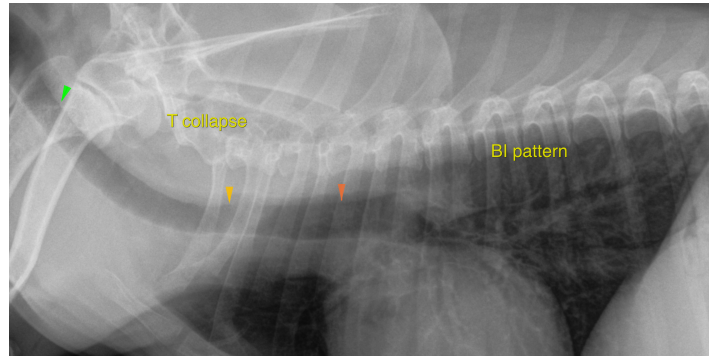
Dr. Castaneda

INVOICE

44626

DATE

8/10/23



The information and recommendations provided are based on the images presented by the referring veterinarian. No evaluation can be communicated regarding pathology that was not visible in the image/video clips provided.

Thank you for this referral. If the clinical or image interpretation does not parallel your findings or if I can be of any further assistance please contact me.

Nele Eley (Ondreka), DVM, Dr. med. vet., DipECVDI
European Specialist in Veterinary Diagnostic Imaging, Cert. Radiology,
Senior lecturer University of Giessen/Germany, Veterinary Faculty, Department of Radiology.
Nele.Eley@sonopath.com