

**PATIENT PRESENTING CLINICAL SIGNS**

Ruby Red Tannous

The patient had a puncture wound (puncture of the area from tree branches, abscess, trauma, or Foreign body in the palatoglossal arch area), top molar right side. She was treated in the other vet but still shows pain when opening her jaw. Eating Habits: Abnormal: On and off depending on the pain

**SPECIES**

Canine

Drinking Habits: Abnormal: On and off depending on the pain Is the patient currently on any medications? Yes, please list: Carprofen Inj 50mg/ml given in hospital 8/9/23, Carprofen 100mg SID up to 8/13/23 but could not get the patient to take meds yesterday and was given the injection instead, Convenia given 8/2/23 SQ injection Current Diet: Soft beef with rice

**BREED**

Hungarian Vizsla

Abnormal PE/Chem/CBC/UA Results: CBC & Chem: all within normal values. PE: Oral Cavity: Tartar mild No swelling of the gum area along the right side of the upper molars and premolars, painful when opening the mouth and opening the jaw area but no swelling was noted from the last visit

**COMPUTED TOMOGRAPHIC STUDY OF THE HEAD**

**SEX**

Spayed Female

Plain and post-contrast studies are available for review.

**AGE**

4 Years 1 Day

Mild right submandibular and medial retropharyngeal lymphadenomegaly is noted.

The right tonsil is slightly enlarged.

No abnormality of the right masticatory muscles, right temporomandibular joint, right maxillary arcade, and right palatoglossal soft tissue can be identified. There is no evidence of foreign material.

**INTERPRETED BY**

Nele Eley (Ondreka),  
DVM Dr. med. vet.,  
DipECVDI

A mild amount of hypoattenuating material is seen medially within the right external auditory meatus.

**COMPUTED TOMOGRAPHIC DIAGNOSIS**

- Right medial retropharyngeal and submandibular lymphadenomegaly, mild
- Mild right-sided otitis externa
- No significant dental changes and no evidence of foreign material noted

**HOSPITAL NAME**

Catskill Vet Services

**INTERPRETATION OF FINDINGS & FURTHER RECOMMENDATIONS**

**REFERRING VET**

Dr. D'Abbraccio

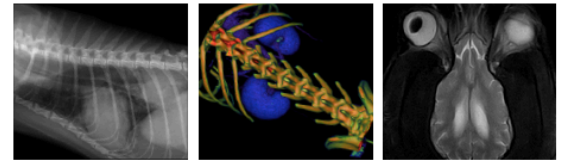
Diagnosis is open. The CT study reveals no significant abnormality within the palatoglossal, gingivostomal and masticatory soft tissues. Nevertheless, mild right medial retropharyngeal and submandibular lymphadenomegaly suggesting reactive hyperplasia is noted, which parallels the clinical history of pathology in the right side of the face. CT occult pathology unfortunately has to be considered a potential, which may be due to the pathology being below the spatial or contrast resolution limits of CT. Note the presence of mild right-sided otitis externa, which is unlikely to explain both the clinical signs as well as the lymph node enlargement.

**INVOICE**

44622

**DATE**

8/10/23



**PATIENT**

Ruby Red Tannous

**SPECIES**

Canine

**BREED**

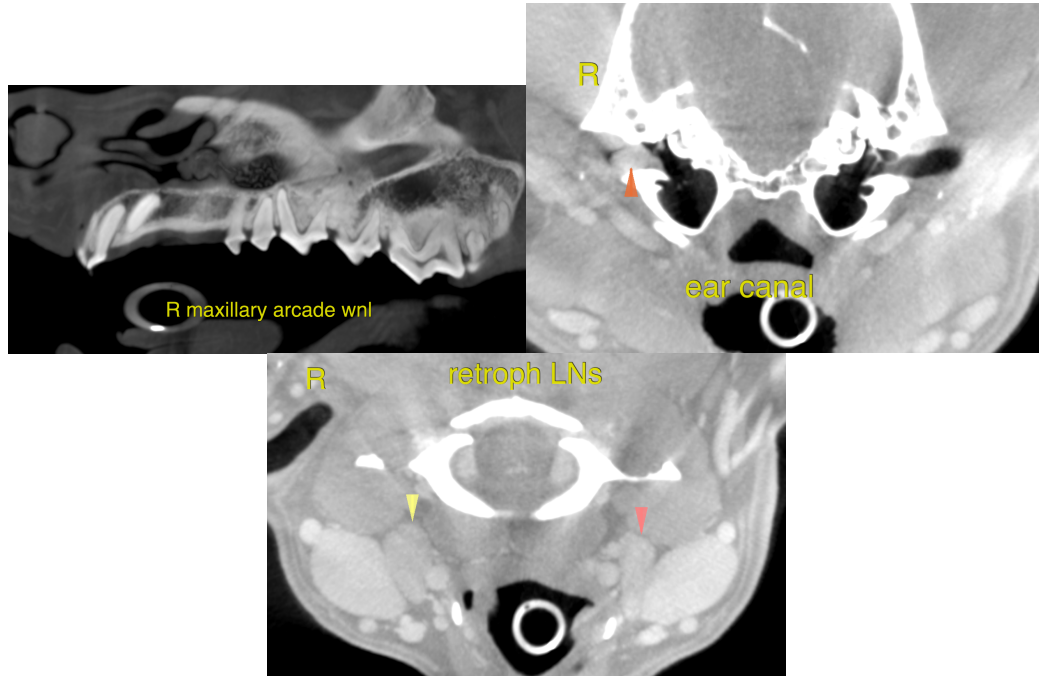
Hungarian Vizsla

**SEX**

Spayed Female

**AGE**

4 Years 1 Day



**The information and recommendations provided are based on the images presented by the referring veterinarian. No evaluation can be communicated regarding pathology that was not visible in the image/video clips provided.**

**INTERPRETED BY**

Nele Eley (Ondreka),  
DVM Dr. med. vet.,  
DipECVDI

Thank you for this referral. If the clinical or image interpretation does not parallel your findings or if I can be of any further assistance please contact me.

**HOSPITAL NAME**

Catskill Vet Services

**Nele Eley (Ondreka)**, DVM, Dr. med. vet., DipECVDI  
European Specialist in Veterinary Diagnostic Imaging, Cert. Radiology,  
Senior lecturer University of Giessen/Germany, Veterinary Faculty, Department of Radiology.  
Nele.Eley@sonopath.com

**REFERRING VET**

Dr. D'Abbraccio

**INVOICE**

44622

**DATE**

8/10/23