
**PATIENT PRESENTING CLINICAL SIGNS**

Dolly Marlor Patient has fever 39.7 C and the right leg swollen and hot, P got bitten by another dog before recent adoption by the existing owner.

**SPECIES RADIOGRAPHIC STUDY OF THE RIGHT FOREARM**

Canine Mediolateral and craniocaudal views of the right forearm totaling 2 images are available for review.

**RADIOGRAPHIC FINDINGS**
**BREED**

English Bulldog

Severe soft tissue swelling is seen circumferential to the right forearm with heterogeneous appearance and gas inclusions. The skin surface appears to be irregular. Brush bordered periosteal new bone formation is seen in the proximal and mid diaphyseal thirds of the radius and ulna. There is reduced regional cortical bone thickening, reduced corticomedullary definition and endosteal thickening of the bone with mild medullary sclerosis of both the radius and ulna. Osteopenia of the metacarpal bones and phalanges is noted. No evidence of traumatic osseous injury. The distal radius and ulnar growth plates present within normal limits.

**SEX**

Female

**RADIOGRAPHIC DIAGNOSIS**
**AGE**

7 Months

- Severe soft tissue swelling with emphysema of the right forearm
- Regional osteopathy of the right radius and ulna

**INTERPRETATION OF FINDINGS & FURTHER RECOMMENDATIONS**
**INTERPRETED BY**

Nele Eley (Ondreka),  
 DVM Dr. med. vet.,  
 DipECVDI

The radiographic findings are highly suggestive for septic cellulitis of the right forearm with regional periostitis and osteomyelitis of the right radius and ulna as a consequence of the prior bite injury. Fractures of the radius and ulna are not seen. The osteopenia of the phalanges is likely a consequence of disuse of the limb. The emphysema can be due to the presence of gas forming bacteria or perforating wounds.

**HOSPITAL NAME**

St. Catharine's AH

**REFERRING VET**

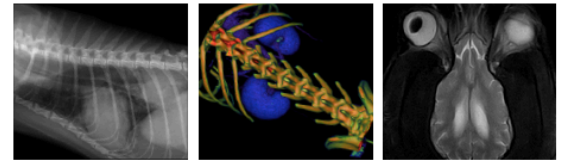
Dr. Adel Williams

**INVOICE**

44591

**DATE**

8/9/23



**PATIENT**

Dolly Marlor

**SPECIES**

Canine

**BREED**

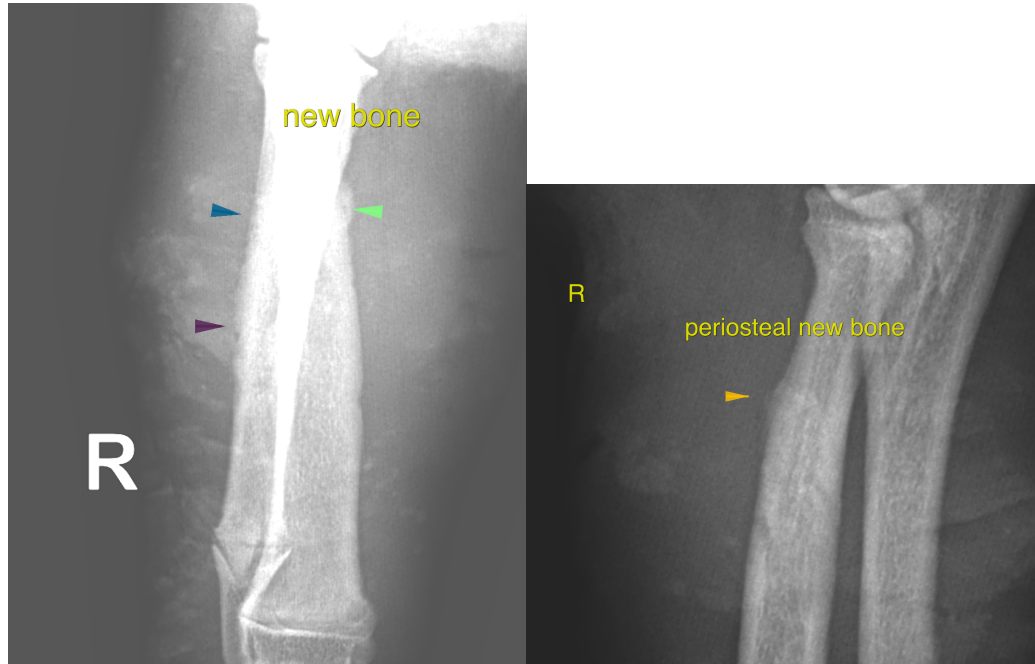
English Bulldog

**SEX**

Female

**AGE**

7 Months



The information and recommendations provided are based on the images presented by the referring veterinarian. No evaluation can be communicated regarding pathology that was not visible in the image/video clips provided.

**INTERPRETED BY**

Nele Eley (Ondreka),  
DVM Dr. med. vet.,  
DipECVDI

Thank you for this referral. If the clinical or image interpretation does not parallel your findings or if I can be of any further assistance please contact me.

**HOSPITAL NAME**

St. Catharine's AH

**Nele Eley (Ondreka)**, DVM, Dr. med. vet., DipECVDI  
European Specialist in Veterinary Diagnostic Imaging, Cert. Radiology,  
Senior lecturer University of Giessen/Germany, Veterinary Faculty, Department of Radiology.  
Nele.Eley@sonopath.com

**REFERRING VET**

Dr. Adel Williams

**INVOICE**

44591

**DATE**

8/9/23