



**PATIENT PRESENTING CLINICAL SIGNS**

**PATIENT** Pepper Santiago Reason for Visit: coughing History: 2yr old SF Longhair is presented today b/c Owner states that really for all of P's life she has coughing fits every day/ every other day sometimes very deep & rapid sometimes not so aggressive & the fits do last about a minute + -. O has been giving Very science Lysine daily to try & help along with Digestive support O also has air purifiers, switched to a biodegradable tree fiber litter with less dust & an open litter box.

**SPECIES** Feline Abnormal PE/Chem/CBC/UA Results: CV/Respiratory: Normal heart rate and rhythm, no murmur, pulses strong and synchronous, normal bronchovesicular sounds. EENT: Clear OU and AU. No nasal discharge. No cough on tracheal palpation. Oral cavity: N Musculoskeletal: BCS = 5/9. Ambulatory x 4 Uro/Perineum: No significant lesions Abd/GI: Soft, non-painful. No masses or fluid wave palpated Lymph Nodes: No peripheral lymphadenopathy Neurological: Alert and appropriate. No significant abnormalities Skin: Good hair coat. No ectoparasites seen Mentation: BAR Hydration: N Fecal: Not performed today

**BREED** DSH

**SEX RADIOGRAPHIC STUDY OF THE THORAX**

**SEX** SF Right lateral and ventrodorsal views totaling 2 images available for review.

**RADIOGRAPHIC FINDINGS**

**AGE** The surrounding bony structures are within normal limits.

2 Years, 9 Months The extrathoracic soft tissues present homogeneous without abnormalities.

**INTERPRETED BY** The heart is of normal size and shape and there is no evidence of cardiac chamber or vascular enlargement. The pulmonary vasculature is within normal limits.

Nele Eley, DVM  
Dr. med. Vet. DipECVDI The cranial mediastinum presents the expected soft tissue opacity. The mediastinal width is less than twice the width of the vertebral column at the same level.

**HOSPITAL NAME** The trachea is normal in diameter and presents the anticipated course. The luminal outline of the trachea is smooth.

DPC Veterinary Hospital The chest is mildly expanded and barrel shaped. Pulmonary inflation is deep. A moderate bronchial lung pattern with marked peribronchial cuffing and mild tree-in-bud appearance is noted throughout the entire lung.

**REFERRING VET** The diaphragm is well delineated with even surface and the expected mild cranial bulging of the diaphragmatic cupola.

**INVOICE** • Bronchial lung pattern with peribronchial cuffing.

53407 **INTERPRETATION OF THE FINDINGS & FURTHER RECOMMENDATIONS**

**DATE** 8-10-22 The radiographic findings are compatible with chronic lower airway disease. Allergic lower airway syndrome with emerging air trapping and active bronchial and peribronchial inflammation is considered likely. Infectious bronchitis or superinfection with allergic airway syndrome cannot be ruled out entirely as differential diagnoses. A clinical trial of treatment for feline asthma could



**PATIENT**

be considered and weighed against immediate further definition by means of airway sampling.

Pepper Santiago

**SPECIES**

Feline

**BREED**

DSH

**SEX**

SF

**AGE**

2 Years, 9 Months

**INTERPRETED BY**

Nele Eley, DVM  
Dr. med. Vet. DipECVDI

**HOSPITAL NAME**

DPC Veterinary  
Hospital

**REFERRING VET**

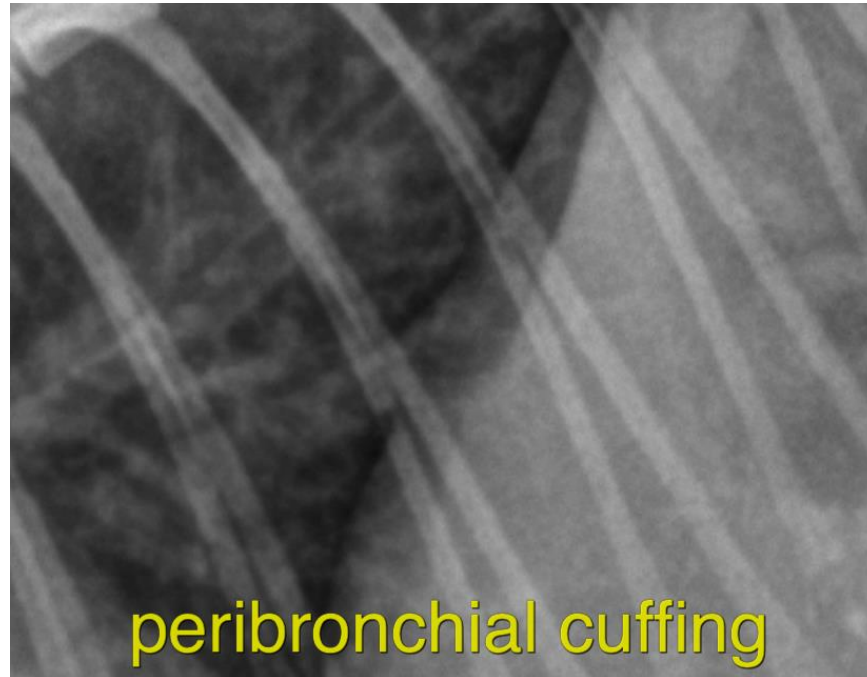
Dr. White

**INVOICE**

53407

**DATE**

8-10-22



**The information and recommendations provided are based on the images presented by the referring veterinarian/sonographer. No evaluation can be communicated regarding pathology that was not visible in the image/video clips provided.**

Thank you for this referral. If the clinical or image interpretation does not parallel your findings or if I can be of any further assistance please contact me.

**Nele Eley**, DVM, Dr. med. vet., DipECVDI  
European Specialist in Veterinary Diagnostic Imaging, Cert. Radiology,  
Senior lecturer University of Giessen, Germany, Veterinary Faculty, Department of Radiology  
Nele.Eley@sonopath.com