

**PATIENT**

Luna Kramer

PRESENTING CLINICAL SIGNS

Last night Luna became lethargic and weak, and her eyes looked glossy. She has been fine up until then.

SPECIES

Canine

Abnormal PE/Chem/CBC/UA Results: Pale pink gums, uncomfortable cranial abdomen, weak femoral pulses, Remainder is normal. CBC: Anemia of chronic disease: RBC 4.89 M/uL, HCT 34%, Hg 11.3 g/dL Eos 0.06 K/uL, PLT 142 K/uL (clumped on smear though). Chem: K barely low at 3.4 mmol/L

BREED

Golden Retriever

RADIOGRAPHIC STUDY OF THE THORAX

Right/left lateral and ventrodorsal views totaling 3 images available for review.

SEX

FS

Mild bilateral elbow osteoarthritis is noted.

The vertebral heart score is 10.3. The radiographic presentation of the cardiac silhouette is within normal limits. No specific chamber enlargement is noted. The pulmonary vasculature and caudal vena cava are thin.

AGE

10 Years, 3 Months

Course and width of the trachea are considered within normal limits.

The lung presents a mild generalized bronchointerstitial pattern which is considered within age related normal limits. No evidence of pulmonary nodules or masses is seen.

INTERPRETED BY

Nele Eley, DVM
Dr. med. Vet. DipECVDI

There is no evidence of mediastinal widening.

The abdominal serosal detail appears to be maintained in the cranial abdomen.

Mild gastric aerophagia is noted.

HOSPITAL NAME

Elizabeth Animal
Hospital

RADIOGRAPHIC DIAGNOSIS

- Normal age related radiographic presentation of the thorax.
- Mild hypovolemia with microcardia and underperfusion of the lung suspected.

REFERRING VET

Kim Allyn, DVM

INTERPRETATION OF THE FINDINGS & FURTHER RECOMMENDATIONS

The radiographic presentation of the bronchopulmonary structures is considered within age related normal limits. No evidence of pulmonary nodules or masses is seen. There is no evidence of mediastinal mass effects.

INVOICE

53409

DATE

8-10-22



PATIENT

Luna Kramer

SPECIES

Canine

BREED

Golden Retriever

SEX

FS

AGE

10 Years, 3 Months

INTERPRETED BY

Nele Eley, DVM
Dr. med. Vet. DipECVDI

HOSPITAL NAME

Elizabeth Animal
Hospital

REFERRING VET

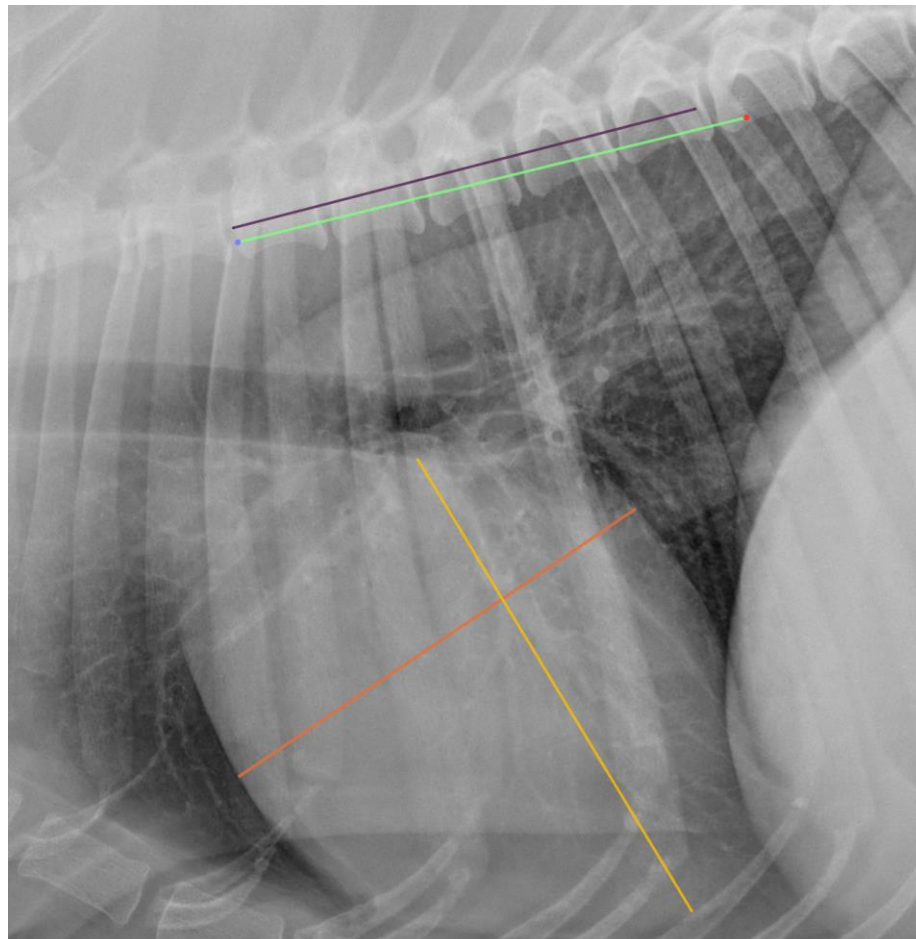
Kim Allyn, DVM

INVOICE

53409

DATE

8-10-22



The information and recommendations provided are based on the images presented by the referring veterinarian/sonographer. No evaluation can be communicated regarding pathology that was not visible in the image/video clips provided.

Thank you for this referral. If the clinical or image interpretation does not parallel your findings or if I can be of any further assistance please contact me.

Nele Eley, DVM, Dr. med. vet., DipECVDI
European Specialist in Veterinary Diagnostic Imaging, Cert. Radiology,
Senior lecturer University of Giessen, Germany, Veterinary Faculty, Department of Radiology
Nele.Eley@sonopath.com