


PATIENT PRESENTING CLINICAL SIGNS

Junipher Canteli Frequent constipation, unable to hold stool (wears diapers), used to suffer from urinary incontinence but has improved. Ataxia affecting pelvic limbs on/off.

SPECIES COMPUTED TOMOGRAPHIC STUDY OF THE SPINE

Canine Plain and post contrast studies of the thoracolumbar spine available for review.

COMPUTED TOMOGRAPHIC FINDINGS
BREED

English Bulldog

Six normally shaped lumbar vertebrae are present. The 7th lumbar vertebra presents a fusion defect of its vertebral arch allowing for dorsal deviation of the dural tube through the defect. The dural tube passes through the defect within the vertebral arch of L7 and fusion between the dural tube and deeper layers of the subcutaneous tissue appears to be present.

SEX

Spayed Female

Incomplete fusion of the dorsal spinous process of the 1st sacral vertebra is seen. The 1st sacral vertebra is partially fused to the remainder of the sacrum.

A sacrococcygeal transition vertebra is present.

AGE

3 Years

The coccygeal spine comprises multiple hemi and block vertebra as typical in corkscrew tail breeds.

COMPUTED TOMOGRAPHIC DIAGNOSIS

- Spina bifida occulta with meningo-/ meningomyelocele L7 & S1.

INTERPRETED BY

Nele Eley (Ondreka),
 DVM Dr. med. vet.,
 DipECVDI

INTERPRETATION OF FINDINGS & FURTHER RECOMMENDATIONS

The CT study reveals meningo/meningomyelocele in the caudal lumbar spine level with L7 secondary to spina bifida. No superficial skin defect can be seen which renders this a case of spina bifida occulta. The meningo- or meningomyelocele per se does not necessarily cause clinical signs unless infected. However, a tethered cord syndrome and malformation, claudication, or inflammation of the cauda equina nerves is likely.

HOSPITAL NAME

Mobile Pet Imaging

REFERRING VET

Meaux

INVOICE

53416

DATE

8-10-22



PATIENT

Junipher Canteli

SPECIES

Canine

BREED

English Bulldog

SEX

Spayed Female

AGE

3 Years

INTERPRETED BY

Nele Eley (Ondreka),
DVM Dr. med. vet.,
DipECVDI

HOSPITAL NAME

Mobile Pet Imaging

REFERRING VET

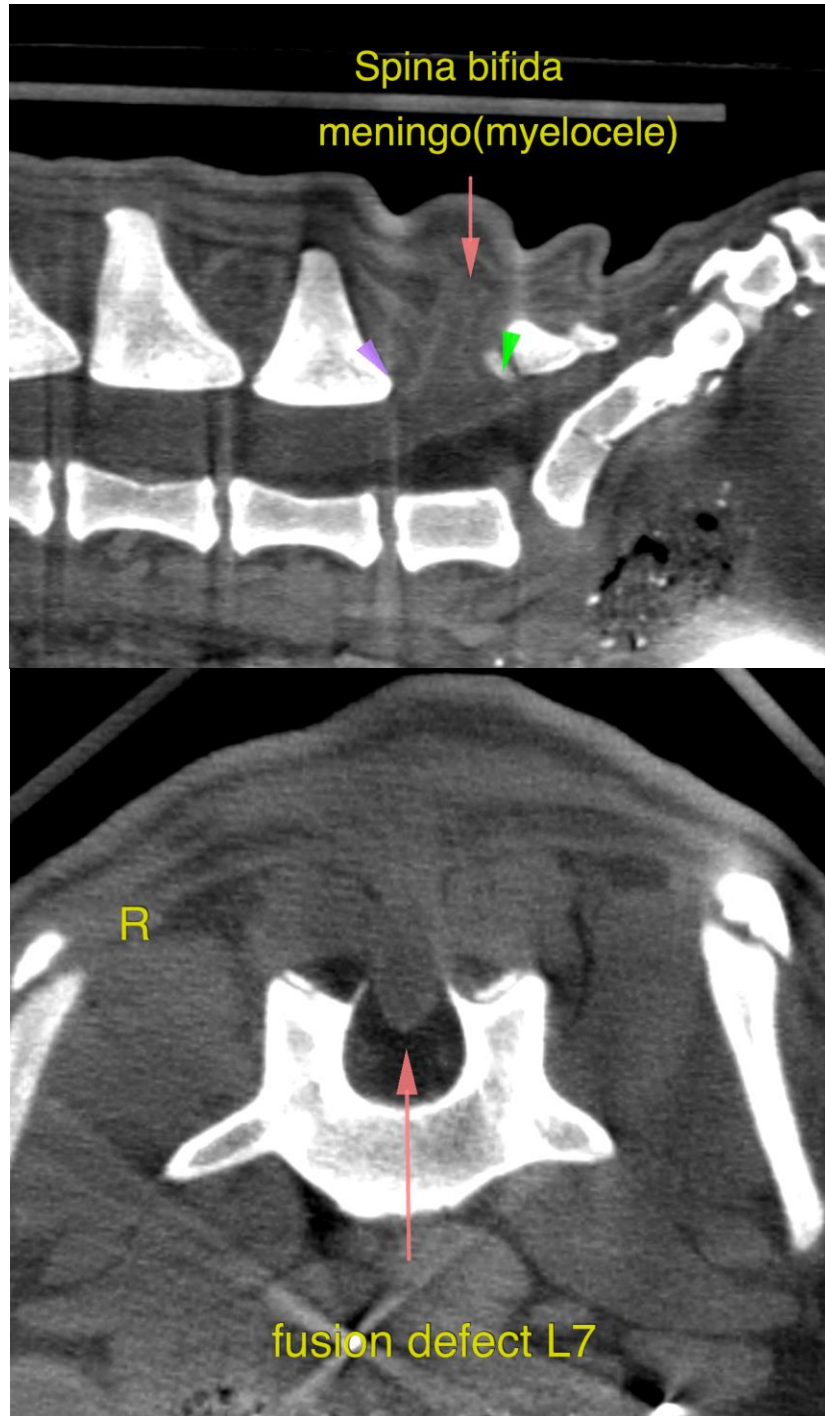
Meaux

INVOICE

53416

DATE

8-10-22





PATIENT

Junipher Canteli

SPECIES

Canine

BREED

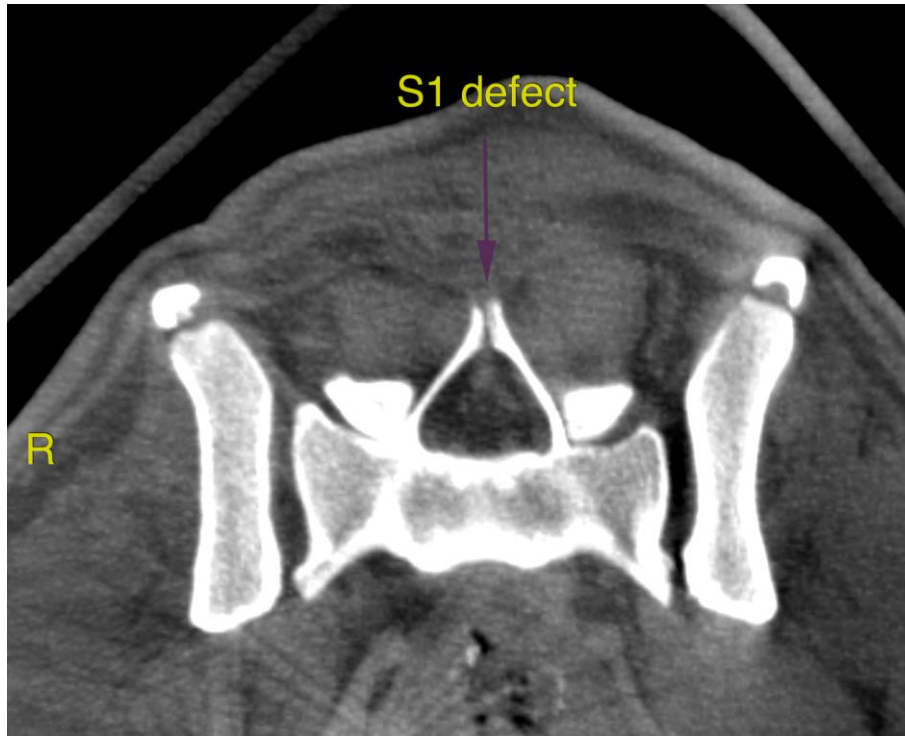
English Bulldog

SEX

Spayed Female

AGE

3 Years



INTERPRETED BY

Nele Eley (Ondreka),
DVM Dr. med. vet.,
DipECVDI

The information and recommendations provided are based on the images presented by the referring veterinarian. No evaluation can be communicated regarding pathology that was not visible in the image/video clips provided.

Thank you for this referral. If the clinical or image interpretation does not parallel your findings or if I can be of any further assistance please contact me.

HOSPITAL NAME

Mobile Pet Imaging

Nele Eley (Ondreka), DVM, Dr. med. vet., DipECVDI
European Specialist in Veterinary Diagnostic Imaging, Cert. Radiology,
Senior lecturer University of Giessen/Germany, Veterinary Faculty, Department of Radiology.
Nele.Eley@sonopath.com

REFERRING VET

Meaux

INVOICE

53416

DATE

8-10-22